

## SUPPLEMENTARY MATERIAL ONLINE

*Retinal artery/arteriole occlusion risks after endovascular treatment for unruptured intracranial aneurysm*

Contents	Page
<b>Supplementary Methods</b>	2-3
<b>Supplementary Table 1.</b> Definitions and codes used for defining medical conditions, comorbidities, drug treatments, and procedures	4
<b>Supplementary Table 2.</b> Characteristics of patients with retinal artery occlusion after endovascular treatment for unruptured intracranial aneurysm	5-6
<b>Supplementary Table 3.</b> Annual new cases and incidence rate of retinal artery occlusion in Korean general population	7
<b>Supplementary Table 4.</b> Comparison of the incidence rate and standardized incidence ratio of retinal artery occlusion in Korean patients with unruptured intracranial aneurysm	8-9
<b>Supplementary Table 5.</b> Case reports and review of the literature on retinal artery occlusion after the treatment of unruptured intracranial aneurysm	10-11
<b>Supplementary Figure 1.</b> Incidence of retinal artery occlusion after the diagnosis of unruptured intracranial aneurysm in untreated patients (A), patients treated with microsurgical clipping (B), and patients treated with endovascular treatment (C)	12
<b>Supplementary Figure 2.</b> Representative cases of retinal artery occlusion after endovascular treatment procedure for unruptured intracranial aneurysm	13

## Supplementary Methods

### *Data source and availability of the nationwide population-based cohort*

This study was a retrospective analysis of the National Health Claims Database established by the Health Insurance Review and Assessment (HIRA) service in Korea. The majority (97%) of the Korean population mandatorily subscribes to the National Health Insurance Service, which is a single insurer managed by the Korean government, with the remaining 3% categorized as medical aid individuals. All raw data can be accessed via the HIRA Healthcare Bigdata Hub server. The application of the claims data submitted through the HIRA Healthcare Bigdata Hub homepage (<https://opendata.hira.or.kr/home.do>) is reviewed by the deliberative committee of research support, and once approved, raw data are provided to the authorized researcher at a fee. After obtaining permission, data were analyzed using remote access to the HIRA server. The entire dataset can be handled only through a connection to the HIRA server, and the analyzed data can be exported with HIRA approval.

### *Data collection for the hospital-based cohort*

The data collected for each patient included the following at baseline: sex, age, date and type of treatment for aneurysm, antiplatelet and anticoagulant medication, presence of hypertension, diabetes, dyslipidemia, chronic kidney disease, and all complications related to endovascular treatment, including intraoperative bleeding, carotid artery dissection, intraoperative thrombus, and post-procedural complications (e.g., transient ischemic attack, ischemic stroke, permanent neurologic deficit, or hemorrhagic complications). Digital subtraction angiography (DSA), computed tomography angiography (CTA), and magnetic resonance imaging before and after the procedure were performed in all patients to confirm the presence of atherosclerosis, carotid artery dissection, and diffusion restriction after treatment. DSA and CTA were performed to evaluate the angioarchitecture of the aneurysm using the Philips Biplane Angiographic System.

### *Routine treatment protocols for endovascular treatment*

All treatment procedures were performed with the patient under general anesthesia. The routine antiplatelet preparations prescribed for endovascular treatment (EVT) of the UIA are per os aspirin (100 mg/day) and clopidogrel (75 mg/day) for at least 5 days before EVT. If the daily regimens were not followed, aspirin and clopidogrel were administered at a loading dose of 300 mg. Systemic heparin was administered after arterial puncture. In line with our embolization protocol, 2,000–3,000 IU of heparin was administered as an intravenous bolus injection, followed by an additional dose of 1,000 IU/hour without routine monitoring of the activated coagulation time and activated partial thromboplastin time.

## Supplementary Tables

**Supplementary Table 1.** Definitions and codes used to define the medical conditions, comorbidities, drug treatments, and procedures

	Definitions	Codes or conditions
<b>Medical conditions</b>		
Unruptured intracranial aneurysm	Defined from diagnosis*	ICD-10: I671
Central retinal artery occlusion	Defined from diagnoses*	ICD-10: H341
Branch retinal artery occlusion	Defined from diagnoses*	ICD-10: H342
Hypertension	Defined from diagnosis*	ICD-10: I10, I11, I12, I13, I15
Diabetes mellitus	Defined from diagnosis*	ICD-10: E10, E11, E12, E13, E14
Dyslipidemia	Defined from diagnosis*	ICD-10: E78
Transient ischemic attack	Defined from diagnosis*	ICD-10: G45
Ischemic stroke	Defined from diagnosis*	ICD-10: I63, I64
Hemorrhagic stroke	Defined from diagnosis*	ICD-10: I60, I61, I62
Myocardial infarction	Defined from diagnosis*	ICD-10: I21, I22, I25.2
Chronic kidney disease	Defined from diagnosis*	ICD-10: N18, N19
Hyperthyroidism	Defined from diagnosis*	ICD-10: E05
Hypothyroidism	Defined from diagnosis*	ICD-10: E03
Chronic liver disease	Defined from diagnosis*	ICD-10: B18, K70, K71, K72, K73, K74, K76.1
Chronic obstructive pulmonary disease	Defined from diagnosis*	ICD-10: J42, J43(except J43.0), J44
<b>Drug treatment (available in South Korea)</b>		
Aspirin		Aspirin
Warfarin		Warfarin
NOAC		Rivaroxaban, Dabigatran, Apixaban, Edoxaban, Enoxaparin, Fondaparinux
Antiplatelet		Clopidogrel, Ticagrelor, Prasugrel, Dipyridamole, Ticlopidine, Eptifibatide, Cilostazole
<b>Procedures</b>		
Microsurgical clipping	Defined from admission diagnosis of unruptured intracranial aneurysm plus claims for microsurgical procedures	ICD-10: I671 Claim codes: S4641 (Cerebral aneurysm-clipping simple) or S4642 (Cerebral aneurysm-clipping complex)
Endovascular treatment	Defined from admission diagnosis of unruptured intracranial aneurysm plus claims for endovascular treatment	ICD-10: I671 Claim codes: M1661 (Embolization-cerebral/aneurysm/assisted) or M1662 (Embolization-cerebral/aneurysm/others)

\*To ensure accuracy, comorbidities were established based on one inpatient or two outpatient records with ICD-10 codes in the database. NOAC, non-vitamin K antagonist oral anticoagulant; ICD-10, International Classification of Diseases-10th edition.

**Supplementary Table 2.** Characteristics of patients with retinal artery occlusion (RAO) after endovascular treatment for unruptured intracranial aneurysm

	Early RAO	Delayed RAO
<b>Number of patients with RAO</b>		
CRAO	5 (20%)	6 (24%)
BRAO	20 (80%)	19 (76%)
<b>Age group</b>		
< 40	1 (4%)	2 (8%)
40-64	16 (64%)	12 (48%)
65-74	6 (24%)	9 (36%)
≥ 75	2 (8%)	2 (8%)
<b>Sex</b>		
Male	8 (32%)	13 (52%)
Female	17 (68%)	12 (48%)
<b>Socioeconomic status*</b>		
Korean National Health Insurance	22 (88%)	25 (100%)
Medical Assistance program Type 1	3 (12%)	0
Others	0	0
<b>Residence</b>		
Urban	14 (56%)	12 (48%)
Rural	11 (44%)	13 (52%)
<b>Comorbidities</b>		
Hypertension	16 (64%)	14 (56%)
Diabetes	4 (16%)	6 (24%)
Dyslipidemia	18 (72%)	13 (52%)
Transient ischemic attack	1 (4%)	0 (0%)
Ischemic stroke	3 (12%)	3 (12%)
Hemorrhagic stroke	1 (4%)	1 (4%)
Myocardial infarction	0	0
Chronic kidney disease	3 (12%)	1 (4%)
Malignancy	2 (8%)	0
Hyperthyroidism	0	0
Hypothyroidism	4 (16%)	2 (8%)
Chronic liver disease	4 (16%)	4 (16%)
COPD	1 (4%)	1 (4%)
<b>CCI</b>		
0	10 (40%)	14 (56%)
1	5 (20%)	3 (12%)
≥ 2	10 (40%)	8 (32%)
<b>Drugs</b>		

	Aspirin	3 (12%)	9 (36%)
	Warfarin	0	0
	NOAC	1 (4%)	0
	Antiplatelet	6 (24%)	7 (28%)
<b>Device</b>			
	Balloon microcatheter	3 (12%)	1 (4%)
	Stent assisted	17 (68%)	16 (64%)
	Flow diverter	1 (4%)	0

\*Socioeconomic status was categorized based on the type of medical insurance received. People who cannot afford 30% of their total medical expenses, which are self-funded Under Korean National Health Insurance, are covered by the Medical Assistance Program.

**Abbreviation:** CRAO, central retinal artery occlusion; BRAO, branch retinal artery occlusion; COPD, chronic obstructive pulmonary disease; CCI, Charlson Comorbidity Index; NOAC, non-vitamin K antagonist oral anticoagulant.

**Supplementary Table 3.** Annual new cases and the incidence rate of retinal artery occlusion in the general population (2018–2019)

Age group	Average annual new cases		Average annual population		Average annual incidence rate*	
	Men	Women	Men	Women	Men	Women
0-4	1	0.5	1009115	958561	0.10	0.05
5-9	0	2.5	1198020	1133733	0.00	0.22
10-14	3.5	1	1198873	1122685	0.29	0.09
15-19	11.5	5	1458324	1340336	0.79	0.37
20-24	8.5	11.5	1784884	1610222	0.48	0.71
25-29	22.5	23.5	1786715	1602706	1.26	1.47
30-34	31	20	1644455	1544700	1.89	1.29
35-39	58.5	40	2036271	1959589	2.87	2.04
40-44	64.5	55	1984570	1923933	3.25	2.86
45-49	130	85.5	2286569	2218589	5.69	3.85
50-54	182	152.5	2123965	2083005	8.57	7.32
55-59	345	231.5	2137856	2128643	16.14	10.88
60-64	406	319.5	1721733	1767057	23.58	18.08
65-69	497.5	342	1153380	1241473	43.13	27.55
70-74	833	337	859312.3	998886.3	96.94	33.74
75-79	522.5	348.5	669380.3	924920.5	78.06	37.68
80-84	272.5	288.5	371498.8	651401	73.35	44.29
85-89	150.5	120	136960	343085.3	109.89	34.98
90-94	31	28.5	35735.5	125403.5	86.75	22.73
≥95	4	4.5	8036.5	34572.75	49.77	13.02
Total	3575	2417	25605652	25713500	13.96	9.40

\*Incidence rate per 100,000 person-years per year.

**Supplementary Table 4.** Comparison of incidence rates and standardized incidence ratios of retinal artery occlusion among Korean patients with unruptured intracranial aneurysm

Age Group	Sex Group	Observational group (Group 1)				Microsurgical clipping group (Group 2)				Endovascular treatment group (Group 3)			
		Observed cases	Sum of person-years	Incidence rate*	Expected Cases	Observed cases	Sum of person-years	Incidence rate*	Expected Cases	Observed cases	Sum of person-years	Incidence rate*	Expected Cases
0~4	Male	0.00	29.19	0.00	0.00	0.00	0.00	NA	0.00	0.00	0.00	NA	0.00
0~4	Female	0.00	25.79	0.00	0.00	0.00	0.00	NA	0.00	0.00	0.00	NA	0.00
5~9	Male	0.00	59.16	0.00	0.00	0.00	3.66	0.00	0.00	0.00	1.96	0.00	0.00
5~9	Female	0.00	55.66	0.00	0.00	0.00	0.00	NA	0.00	0.00	0.00	NA	0.00
10~14	Male	0.00	208.69	0.00	0.00	0.00	0.03	0.00	0.00	0.00	0.00	NA	0.00
10~14	Female	0.00	203.61	0.00	0.00	0.00	1.64	0.00	0.00	0.00	20.46	0.00	0.00
15~19	Male	0.00	708.02	0.00	0.01	0.00	9.79	0.00	0.00	0.00	46.76	0.00	0.00
15~19	Female	0.00	695.22	0.00	0.00	0.00	2.28	0.00	0.00	0.00	27.55	0.00	0.00
20~24	Male	0.00	1431.59	0.00	0.01	0.00	38.58	0.00	0.00	0.00	57.21	0.00	0.00
20~24	Female	0.00	1530.85	0.00	0.01	0.00	7.59	0.00	0.00	0.00	84.47	0.00	0.00
25~29	Male	0.00	2379.59	0.00	0.03	0.00	46.58	0.00	0.00	0.00	143.84	0.00	0.00
25~29	Female	0.00	2754.30	0.00	0.04	0.00	30.28	0.00	0.00	0.00	216.00	0.00	0.00
30~34	Male	1.00	3933.04	25.43	0.07	0.00	122.53	0.00	0.00	0.00	380.88	0.00	0.01
30~34	Female	2.00	4205.18	47.56	0.05	0.00	117.12	0.00	0.00	0.00	548.37	0.00	0.01
35~39	Male	0.00	7496.64	0.00	0.22	0.00	380.64	0.00	0.01	0.00	992.55	0.00	0.03
35~39	Female	0.00	8507.11	0.00	0.17	0.00	451.29	0.00	0.01	3.00	1418.01	211.56	0.03
40~44	Male	2.00	9738.31	20.54	0.32	0.00	631.58	0.00	0.02	1.00	1623.33	61.60	0.05
40~44	Female	2.00	12350.09	16.19	0.35	0.00	823.88	0.00	0.02	2.00	2346.98	85.22	0.07
45~49	Male	1.00	15379.45	6.50	0.87	0.00	1283.33	0.00	0.07	1.00	2658.50	37.62	0.15
45~49	Female	1.00	22237.83	4.50	0.86	0.00	1863.01	0.00	0.07	2.00	4470.96	44.73	0.17
50~54	Male	4.00	19862.57	20.14	1.70	0.00	1717.27	0.00	0.15	4.00	3141.13	127.34	0.27



50~54	Female	7.00	33129.39	21.13	2.43	0.00	2829.23	0.00	0.21	2.00	6563.19	30.47	0.48	
55~59	Male	6.00	28678.33	20.92	4.63	1.00	2506.84	39.89	0.40	4.00	4401.70	90.87	0.71	
55~59	Female	4.00	49806.59	8.03	5.42	0.00	4926.69	0.00	0.54	7.00	9234.69	75.80	1.00	
60~64	Male	9.00	29323.18	30.69	6.91	0.00	2181.06	0.00	0.51	2.00	4009.77	49.88	0.95	
60~64	Female	3.00	51576.62	5.82	9.33	1.00	5382.08	18.58	0.97	3.00	9361.40	32.05	1.69	
65~69	Male	16.00	25228.05	63.42	10.88	3.00	1618.71	185.33	0.70	4.00	2660.93	150.32	1.15	
65~69	Female	12.00	45374.84	26.45	12.50	1.00	4676.11	21.39	1.29	5.00	7976.84	62.68	2.20	
70~74	Male	28.00	22235.94	125.92	21.56	0.00	896.16	0.00	0.87	4.00	2064.96	193.71	2.00	
70~74	Female	21.00	40557.41	51.78	13.68	0.00	3113.13	0.00	1.05	2.00	6477.62	30.88	2.19	
75~79	Male	10.00	17752.12	56.33	13.86	1.00	385.18	259.62	0.30	0.00	1240.13	0.00	0.97	
75~79	Female	19.00	42682.96	44.51	16.08	0.00	1609.10	0.00	0.61	2.00	5083.24	39.34	1.92	
80~84	Male	6.00	9350.26	64.17	6.86	0.00	49.06	0.00	0.04	1.00	365.99	273.23	0.27	
80~84	Female	9.00	27905.87	32.25	12.36	0.00	296.35	0.00	0.13	1.00	1962.30	50.96	0.87	
85~89	Male	4.00	3107.48	128.72	3.41	0.00	16.89	0.00	0.02	0.00	62.48	0.00	0.07	
85~89	Female	2.00	10672.29	18.74	3.73	0.00	29.02	0.00	0.01	0.00	398.08	0.00	0.14	
90~94	Male	0.00	518.72	0.00	0.45	0.00	0.00	NA	0.00	0.00	9.28	0.00	0.01	
90~94	Female	0.00	2188.21	0.00	0.50	0.00	8.50	0.00	0.00	0.00	63.53	0.00	0.01	
95~	Male	0.00	57.60	0.00	0.03	0.00	0.00	NA	0.00	0.00	0.00	NA	0.00	
95~	Female	0.00	337.88	0.00	0.04	0.00	0.00	NA	0.00	0.00	3.22	0.00	0.00	
Total		169	554275.63	30.49	149.37	7	38055.18	18.39	8.01	50	80118.34	62.41	17.41	
		Age-, sex-adjusted SIR 1.13 (95% CI, 0.93–1.19) <i>p</i> = 0.120					Age-, sex-adjusted SIR 0.87 (95% CI, 0.51–1.75) <i>p</i> = 0.713					Age-, sex-adjusted SIR 2.87 (95% CI, 1.24–4.02) <i>p</i> < 0.001		

\*Incidence rate per 100,000 person-years.

**Abbreviations;** NA, not applicable; SIR, standardized incidence ratio; CI, confidence interval.

**Supplementary Table 5.** Case reports and literature review of retinal artery occlusion after the treatment of unruptured intracranial aneurysm

	Age	Location of aneurysm	Size of aneurysm (mm)	Technique and device use	Types of RAO	Time taken from treatment to vision decrease	Initial visual acuity	Final visual acuity
Present study (Patient 1)	50s	ICSHA	7.1	Simple double catheter	BRAO	1 day	1.0	1.0
Present study (Patient 2)	50s	ICSHA	6.3	Balloon-assisted single catheter	CRAO	1 day	HM	FC
Present study (Patient 3)	50s	ICPCOM	4.2	Stent-assisted single catheter	Retinal arteriole occlusion	1 day	0.9	0.3
Present study (Patient 4)	40s	ICC2	6.4	Stent-assisted single catheter	Retinal arteriole occlusion	1 day	1.0	1.0
Present study (Patient 5)	40s	ICSHA	5.4	Balloon-assisted single catheter	Retinal arteriole occlusion	1 day	0.8	1.0
Present study (Patient 6)	30s	Ophthalmic artery	5.9	Balloon-assisted single catheter	Retinal arteriole occlusion	1 day	1.0	Not assessed
Present study (Patient 7)	40s	ICSHA	5.4	Stent-assisted double catheter	Retinal arteriole occlusion	1 day	1.0	Not assessed
Present study (Patient 8)	60s	Ophthalmic artery	3.3	Flow diverter	Retinal arteriole occlusion	1 day	0.9	0.9
Present study (Patient 9)	40s	ICC2	9.4	Flow diverter	Retinal arteriole occlusion	2 days	0.2	0.5
Present study (Patient 10)	50s	ICC2	5.4	Flow diverter	Retinal arteriole occlusion	1 day	0.6	0.9
Present study (Patient 11)	50s	ICC2	3.9	Balloon-assisted flow diverter	Retinal arteriole occlusion	1 day	0.3	0.6
Choudhry et al. 2011 <sup>1)</sup>	40s	Para-ophthalmic artery	7 x 7 (with 4 mm neck)	Stent-assisted coil embolization	BRAO	12 hours	Not described	Not described
Choudhry et al. 2014 <sup>2)</sup>	40s	Paraclinoid artery	7.1	Not described	BRAO	Several hours	HM	1.0
Castillo et al. 2000 <sup>3)</sup>	50s	Carotid-ophthalmic artery	4	Coil embolization	CRAO	8 hours	HM	Not described
Castillo et al. 2000 <sup>3)</sup>	10s	Ophthalmic branch of carotid artery	8.6	Coil embolization	BRAO	48 hours, right after the cessation of heparin	1.0	Persistent infero-nasal visual field defect
Yoo et al. 2016 <sup>4)</sup>	50s	Paraclinoid artery	6.7 (with a bleb)	Stent-assisted coil embolization	CRAO	8 hours	Total blindness	FC
Wang et al. 2019 <sup>5)</sup>	50s	Internal carotid artery	4.2 x 3.8 x 3.2 (with 3.9 mm neck)	Stent-assisted coil embolization	CRAO	Immediate	FC	Not described
Park et al. 2019 <sup>6)</sup>	40s	Internal carotid artery at the ophthalmic artery orifice	9.3 x 10.6 x 9.6 (with 4.3 mm neck)	Stent-assisted coil embolization	CRAO	Immediate	Not described	Normal vision
Elkordy et al. 2016 <sup>7)</sup>	60s	Ophthalmic artery	6.9 x 5.9 x 4.6 (with 6 mm neck)	Balloon-assisted coil embolization	CRAO	15 minutes	Total blindness	Normal vision

Bae et al. 2021 <sup>8)</sup>	70s	Anterior communication artery	6.2	Coil embolization	Cilioretinal artery occlusion, BRAO	1 day	0.3	0.6
Blautain et al. 2021 <sup>9)</sup>	70s	Internal carotid artery near ophthalmic artery	Not described	Stent-assisted coil embolization	BRAO	2 days	1.0	Not described
Bonnet et al. 2013 <sup>10)</sup>	10s	Internal carotid artery	4.7×4.1×3.5 cm	Coil embolization	BRAO	2 days	1.0	Persistent supero-nasal scotoma
Shin et al. 2018 <sup>11)</sup>	40s	Distal internal carotid artery	Not described	Coil embolization	BRAO	Immediate	1.0	0.8

**Abbreviations;** RAO, retinal artery occlusion; ICSHA, internal carotid artery-superior hypophyseal artery; ICPCOM, internal carotid artery-posterior communicating artery; ICC2, C2 segment of internal carotid artery; BRAO, branch retinal artery occlusion; CRAO, central retinal artery occlusion; HM, hand motion; FC, finger count.

References; 1) Chowdhry S, Sharma J, Blackham K. E-001 Partial central retinal artery occlusion following para-ophthalmic artery embolization: a case report. *Journal of NeuroInterventional Surgery*. 2011;3:A31-A31.

2) Choudhry N, Brucker AJ. Branch retinal artery occlusion after coil embolization of a paraclinoid aneurysm. *Ophthalmic Surg Lasers Imaging Retina*. 2014;45 Online:e26-e28.

3) Castillo B Jr, De Alba F, Thornton J, DeBrun G, Pulido J. Retinal artery occlusion following coil embolization of carotid-ophthalmic aneurysms. *Arch Ophthalmol*. 2000;118:851-852.

4) Yoo M, Jin SC, Kim HY, Choi BS. Intra-arterial Thrombolysis for Central Retinal Artery Occlusion after the Coil Embolization of Paraclinoid Aneurysm. *J Cerebrovasc Endovasc Neurosurg*. 2016;18:369-372.

5) Wang YL, Hui YN, Chen R, Jin YY, Tao J, Zhou YM. Central retinal artery occlusion after endovascular coil embolization for internal carotid artery aneurysm. *Int J Ophthalmol*. 2019;12:520-522.

6) Park H, Nakagawa I, Yokoyama S, et al. Central Retinal Artery Thromboembolism without Ophthalmic Artery Occlusion During Stent-Assisted Coil Embolization of Ophthalmic Artery Aneurysm. *World Neurosurg*. 2019;121:77-82.

7) Elkordy AM, Sato K, Inoue Y, et al. Central Retinal Artery Occlusion after the Endovascular Treatment of Unruptured Ophthalmic Artery Aneurysm: A Case Report and a Literature Review. *NMC Case Rep J*. 2016;3:71-74.

8) Bae H, Kang T, Jeong DE, Shim K, Kang M. Cilioretinal Artery Occlusion after Endovascular Coil Embolization for Anterior Communicating Artery. *Brain Sci*. 2021;11:542.

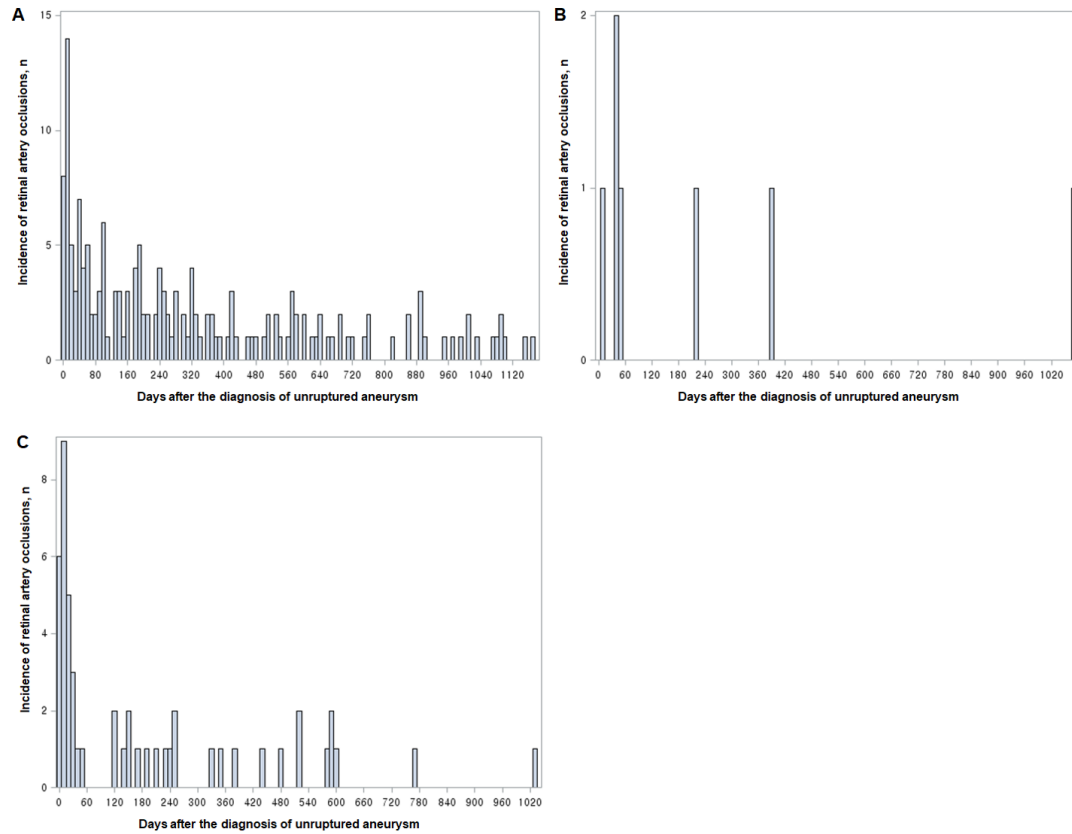
9) Blautain B, Leleu I, Jabbour E, Mer YL. Ischemic stroke and retinal artery occlusion after carotid aneurysm embolization. *Radiol Case Rep*. 2021;16:701-703.

10) Bonnet S, Ellis B, Carpenter JS, Nguyen J. Delayed Branch Retinal Artery Occlusion and Partial Oculomotor Nerve Palsy Following Coiling of a Giant Intracavernous Carotid Artery Aneurysm. *J Ocular Biol*. 2013;1: 4.

11) Shin SH, Park SP, Kim YK. Multiple small branch retinal arteriolar occlusions following coil embolization of an internal carotid artery aneurysm. *Indian J Ophthalmol*. 2018;66:1208-1210.

**Supplementary Figure Legend**

**Supplementary Figure 1.** Incidence of retinal artery occlusion after the diagnosis of unruptured intracranial aneurysm in untreated patients (A), patients treated with microsurgical clipping (B), and patients treated with endovascular treatment (C)



**Supplementary Figure 2.** Representative cases of retinal artery occlusion after endovascular treatment procedure for unruptured intracranial aneurysm. Retinal opacity of the posterior fundus and diffuse hyper-reflective bands along the inner nuclear layer and outer nuclear layer (paracentral acute middle maculopathy-like lesions) were prominent in all cases, reflecting retinal ischemia in the affected areas. Multifocal arteriolar occlusive lesions observed in patients were likely to be caused by procedure-related thrombosis.

