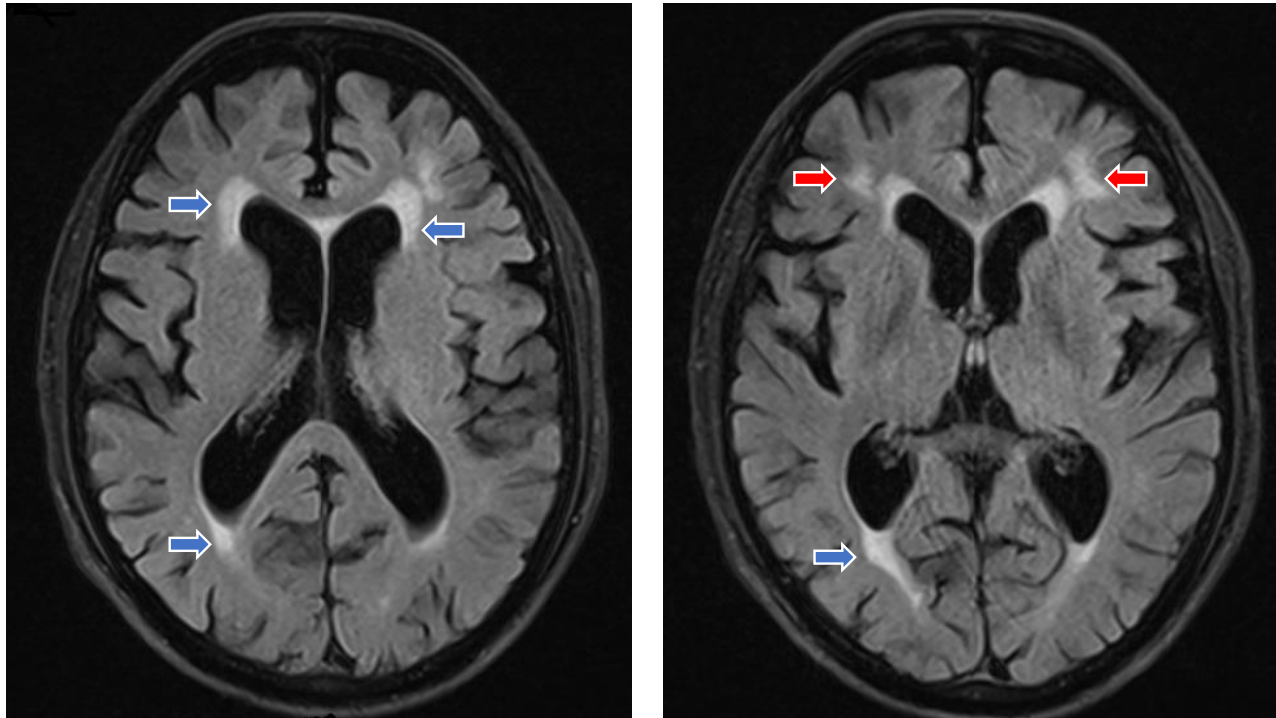
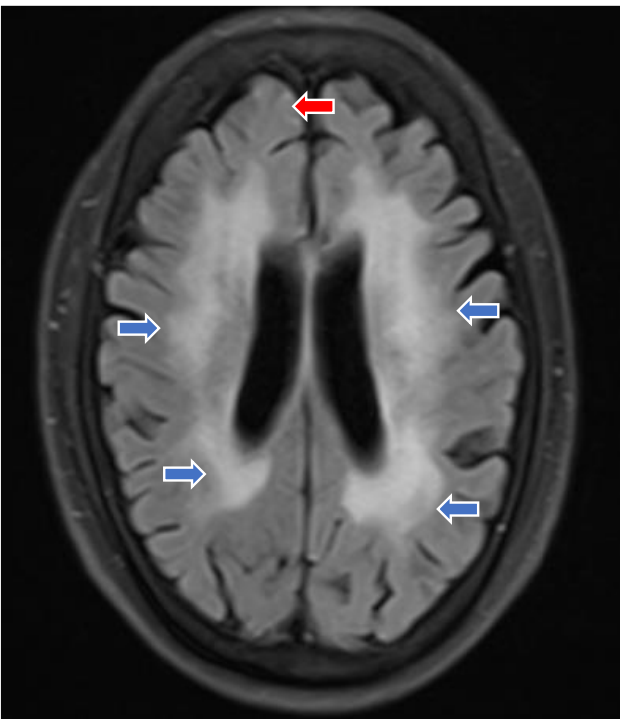


**Supplemental Figure 1. Brain magnetic resonance imaging (MRI) T2-weighted fluid-attenuated inversion recovery (T2-FLAIR) images of patients harboring GGC repeat expansions in *NOTCH2NLC*.**

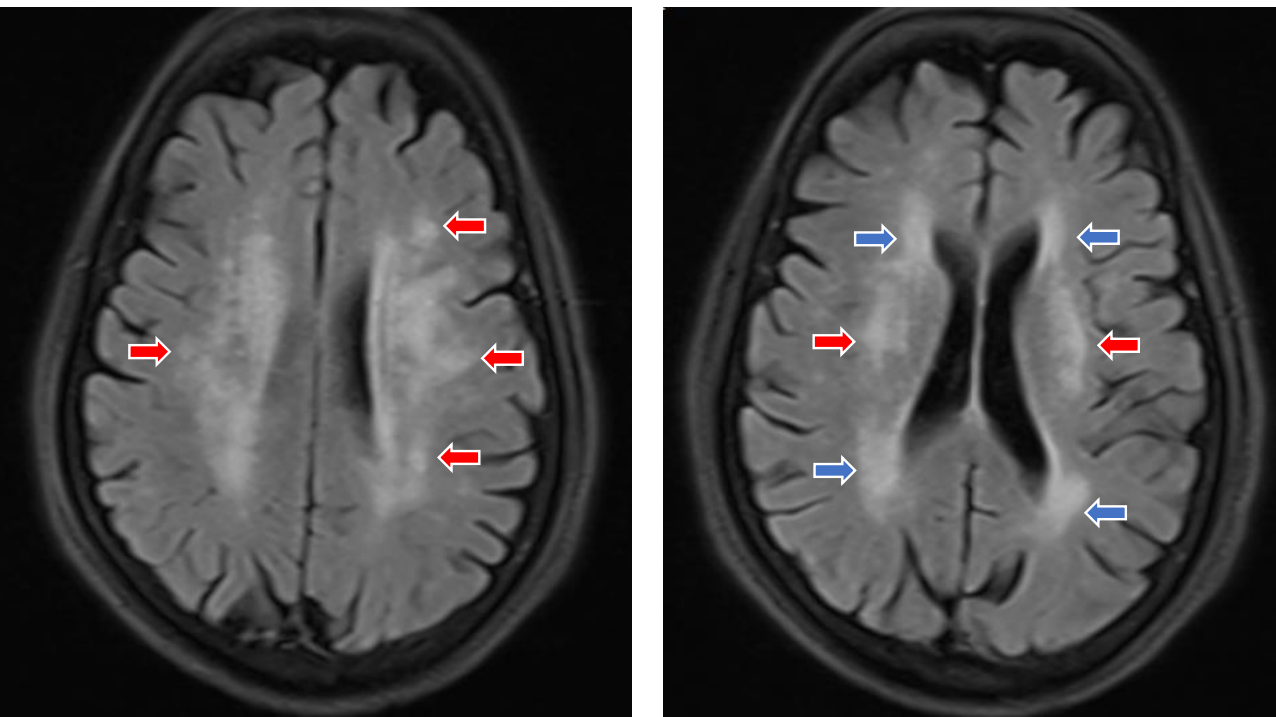
Patient 1



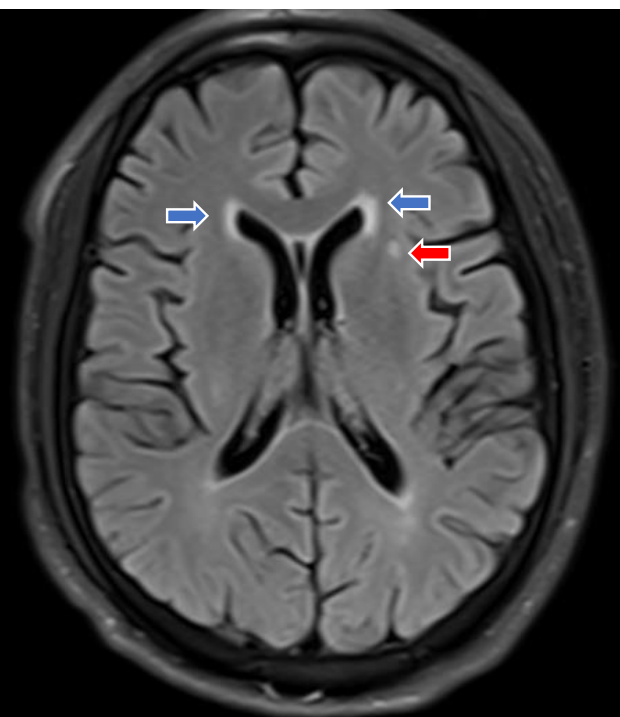
Patient 2



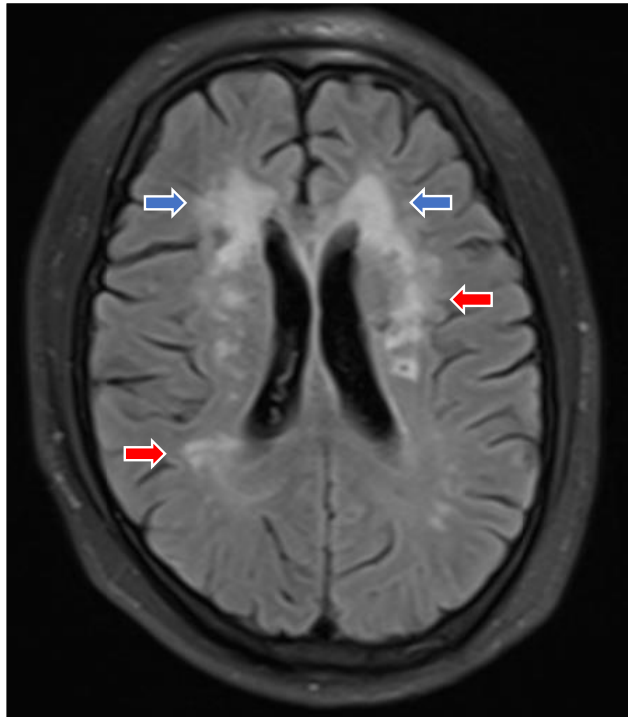
Patient 3



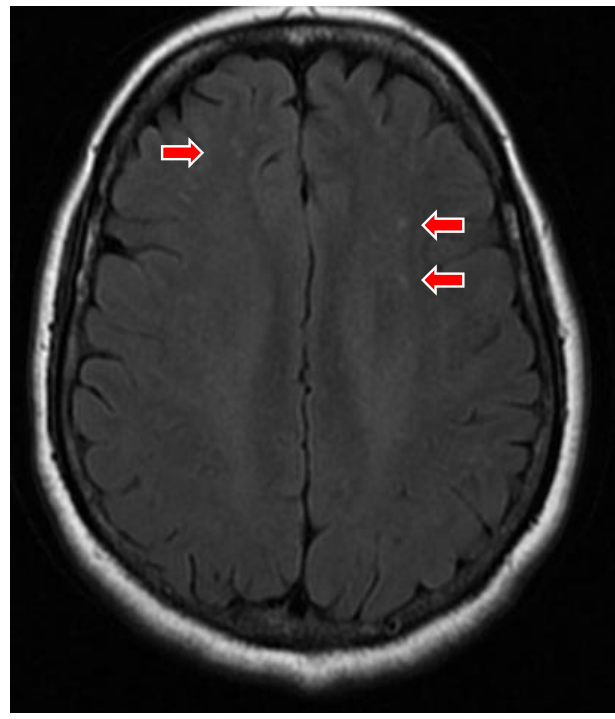
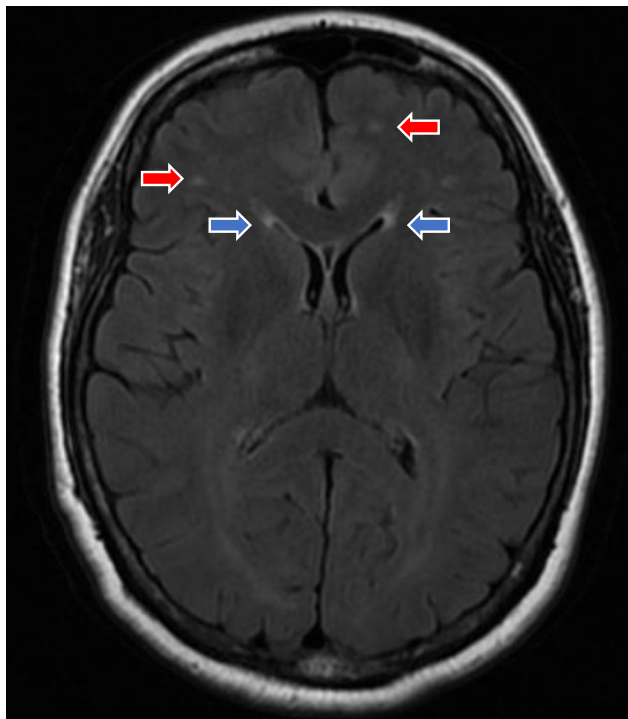
Patient 4



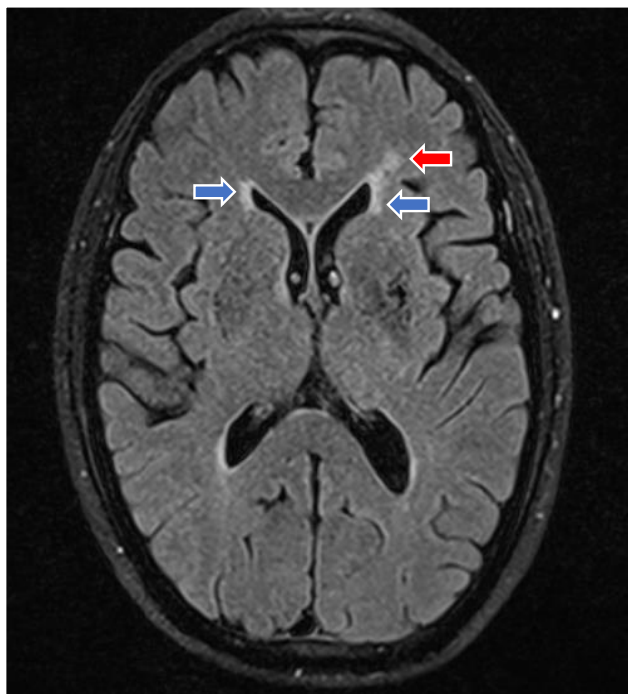
Patient 5



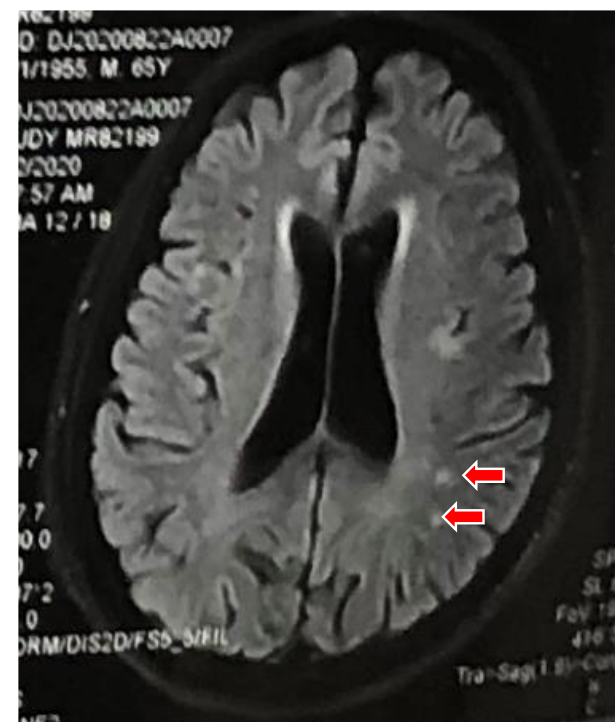
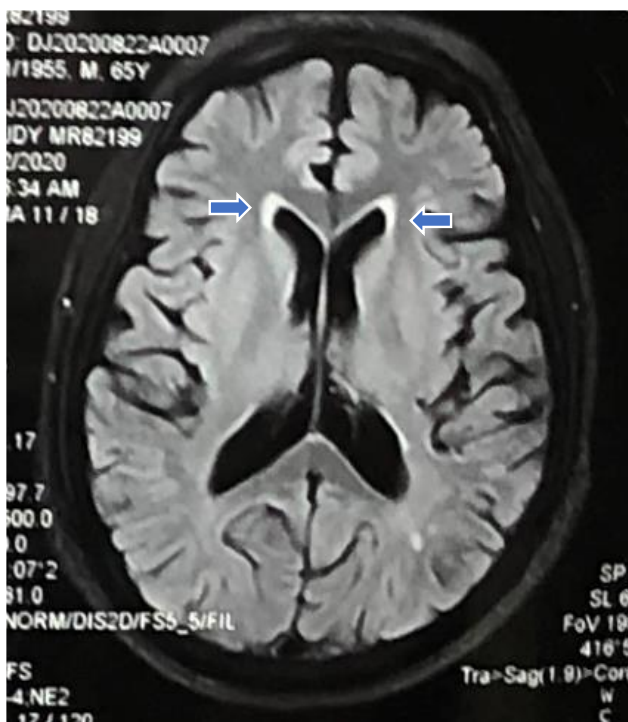Patient 6



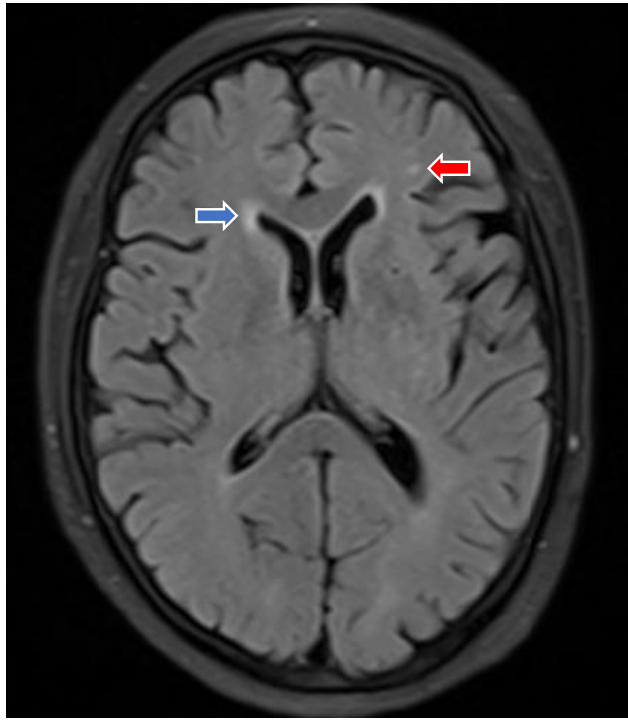
Patient 7



Patient 8



Patient 9



Blue arrow points to periventricular WMH, red arrow points to deep WMH.