








Endovascular treatment for basilar artery occlusion: a meta-analysis

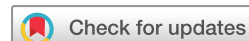Jiawen Xu ¹, Xi Chen,¹ Shidong Chen,¹ Wenjie Cao ¹, Hongchen Zhao ¹, Wei Ni,² Yanrong Zhang,³ Chao Gao,² Yuxiang Gu ², Xin Cheng ¹, Yi Dong ¹, Qiang Dong ¹

To cite: Xu J, Chen X, Chen S, *et al.* Endovascular treatment for basilar artery occlusion: a meta-analysis. *Stroke & Vascular Neurology* 2023;**8**: e001740. doi:10.1136/svn-2022-001740

► Additional supplemental material is published online only. To view, please visit the journal online (<http://dx.doi.org/10.1136/svn-2022-001740>).

JX and XC contributed equally.

Received 17 May 2022
Accepted 5 July 2022
Published Online First
5 August 2022



© Author(s) (or their employer(s)) 2023. Re-use permitted under CC BY-NC. No commercial re-use. See rights and permissions. Published by BMJ.

¹Department of Neurology, Huashan Hospital Fudan University, Shanghai, China

²Department of Neurosurgery, Huashan Hospital Fudan University, Shanghai, China

³Department of Nursing, Huashan Hospital Fudan University, Shanghai, China

Correspondence to

Dr Qiang Dong;
dong_qiang@fudan.edu.cn

Dr Yi Dong; drdongyi@yeah.net

Acute basilar artery occlusion (BAO) may lead to severe disability or death in about 70% of patients.^{1 2} Previous studies have established endovascular treatment (EVT) as the standard treatment for patients with acute anterior circulation occlusions.^{3–9} However, the ideal effective treatment for acute BAO remains controversial.

Two previously published randomised control studies (RCTs), BEST (Basilar Artery Occlusion Endovascular Intervention versus Standard Medical Treatment) and BASICS (Basilar Artery International Cooperation Study), failed to achieve an advantage of EVT over standard medical treatment (SMT).^{10 11} Recently, two other RCTs from China, ATTENTION (Endovascular Treatment For Acute Basilar Artery Occlusion: A Multicentre Randomised Clinical Trial) and BAOCHE (Basilar Artery Occlusion Chinese Endovascular), were presented at the European Stroke Organisation Conference 2022.^{12 13} The ATTENTION trial showed that EVT was associated with the better functional outcomes at 90 days, achieving a higher rate of modified Rankin Scale (mRS) score of ≤ 3 (46.0% vs 22.8%; adjusted relative risk (aRR) 2.1, 95% CI 1.5 to 3.0, $p < 0.001$; number needed to treat (NNT)=4) and $mRS \leq 2$ (33.2% vs 10.5%; aRR 3.2, 95% CI 1.8 to 5.4, $p < 0.001$; NNT=4.4). There was also a significantly lower risk of 90-day mortality (36.7% vs 55.3%; aRR 0.7, 95% CI 0.5 to 0.8, $p < 0.001$; NNT=5.4) but a higher incidence of symptomatic intracranial haemorrhage (sICH, Safe Implementation of Thrombolysis in Stroke—Monitoring Study (SITS-MOST) criteria, EVT 5.3% vs SMT 0%, $p = 0.001$; NNT=19). Likewise, the BAOCHE trial demonstrated that patients receiving EVT had a higher rate of mRS 0–3 (46.4% vs 24.3%, adjusted OR 2.92, 95% CI 1.56 to 5.47, $p = 0.001$; NNT=4.5), trends towards lower mortality (EVT 30.9% vs SMT 42.1%, $p = 0.088$) and a higher risk of sICH (SITS-MOST criteria, EVT 5.9% vs SMT 1.1%, $p = 0.125$). These findings showed the efficacy

of EVT, which could be a turning point for the treatment of acute BAO.

Here, we provided a brief meta-analysis of the aggregate data from BASICS, BEST, ATTENTION and BAOCHE trials according to the intention-to-treat principle. Key features of the design of included trials are summarised in online supplemental table 1. We found that EVT for ischaemic stroke due to acute BAO was correlated with improved functional outcomes compared with SMT. The pooled RR for 90-day mRS 0–3 was 1.54 (95% CI 1.16 to 2.04; heterogeneity $I^2 = 60\%$) (figure 1A). The pooled RR for 90-day mRS 0 to 2 was 1.83 (95% CI 1.08 to 3.08; heterogeneity $I^2 = 79\%$). Although there was a higher risk of sICH (RR 7.77, 95% CI 2.36 to 25.59; heterogeneity $I^2 = 0\%$) (figure 1B), EVT significantly decreased the risk of 90-day mortality (RR 0.76, 95% CI 0.65 to 0.89; heterogeneity $I^2 = 0\%$) (figure 1C). We found no evidence of publication bias using Egger's test ($p > 0.05$).

MERITS AND SHORTCOMINGS

The BEST and BASICS trials had partially similar inclusion criteria and evaluated patients with acute BAO within 8 hours or 6 hours of symptom onset, respectively. The BEST and BASICS both revealed the trend towards favourable outcomes (mRS 0–3) with EVT, but without statistically significant differences. In the meanwhile, both trials had the limitations of poor enrollment and high cross-over rates. Nearly 29% of eligible patients in BASICS group and 55% of patients in BEST group were treated outside trials, which might introduce bias in the enrolled population.¹⁴ The BASICS also had two protocol changes in the midst of the trial due to slow enrollment. Considering these problems, an individual meta-analysis redefined the target population as patients with baseline NIHSS (National Institutes of Health Stroke Scale) score ≥ 10 and found EVT strongly associated

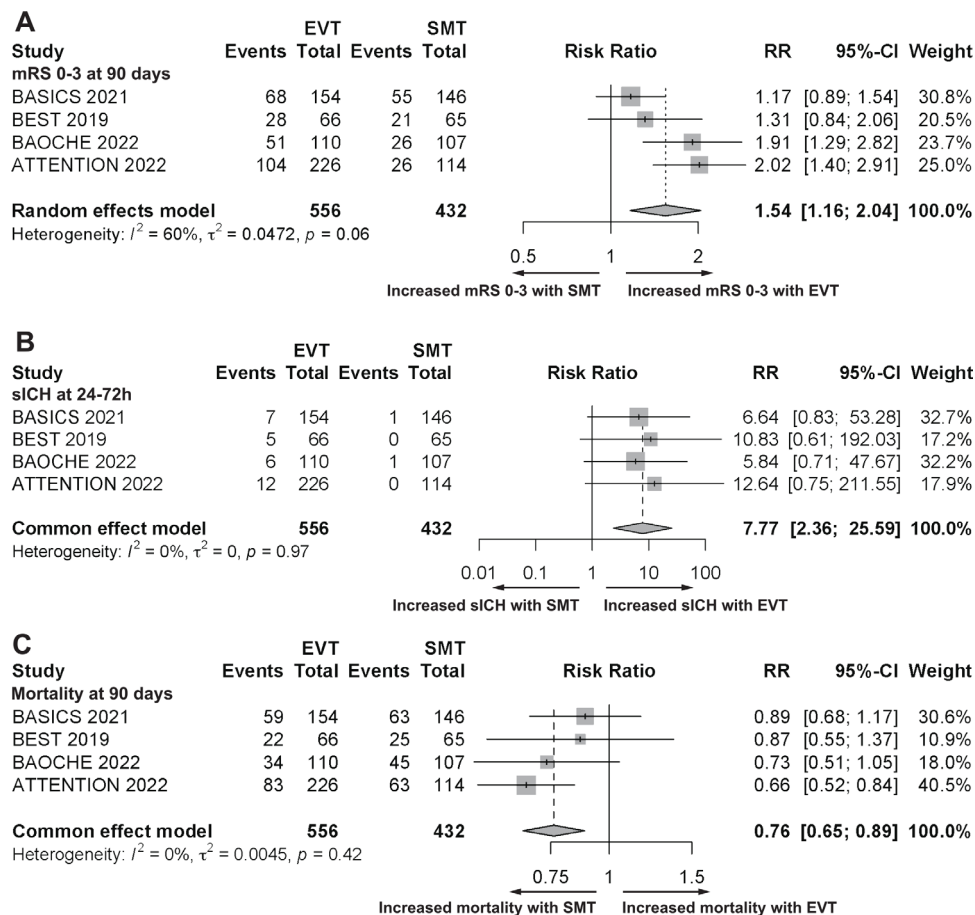


Figure 1 Meta-analysis of the efficacy and safety outcomes of four randomised trials. (A) Forest plot of mRS 0–3 at 90 days; (B) Forest plot of sICH (Heidelberg criteria in the BASICS; SITS-MOST criteria in the ATTENTION and BAOICHE; evidence of intracranial haemorrhage on imaging and an increase of 4 or more points on the NIHSS within 24 hours after randomisation in the BEST); (C) Forest plot of mortality at 90 days. ATTENTION, Endovascular Treatment For acute Basilar Artery Occlusion: A Multicentre Randomised Clinical Trial; BAOICHE, Basilar Artery Occlusion Chinese Endovascular; EVT, endovascular thrombectomy; mRS, modified Rankin Scale; SMT, standard medical treatment; sICH, symptomatic intracerebral haemorrhage.

with favourable clinical outcomes in both intention-to-treat and per-protocol analysis.¹⁵

Previous reports found that the efficacy of EVT might be related to the patients' clinical severity. The ATTENTION and BAOICHE trials, therefore, excluded patients with mild strokes. Both trials followed the protocol strictly so the crossover rates were effectively reduced. The ATTENTION selected 36 high-volume endovascular stroke centres as participating centres, which led to the completion of enrollment within almost 1 year. With the better-designed protocol and good follow-through, the results from ATTENTION and BAOICHE trials could be more persuasive.

Our analysis of the combined trial data further confirmed the benefit of EVT for BAO. Although there was a higher risk of sICH, the EVT might bring better functional outcomes and a lower risk of all-cause mortality at 90 days than the SMT group. These findings can provide more evidence to support EVT for BAO in real-world clinical practice.

However, several limitations in our analysis should be acknowledged. First, the results of two included

RCTs were unpublished and non-peer-reviewed, which may introduce the inherent risk of bias and lack more detailed results of RCTs. Second, high heterogeneity was found in the 90-day clinical outcome measured by mRS. This might be from the different therapeutic time windows defined in these four RCTs, which may affect the percentage of eligible patients for intravenous thrombolysis. Lastly, the BEST, ATTENTION and BAOICHE were restricted to Han Chinese patients, so caution should be exercised when generalising these findings to other ethnic groups.

FUTURE DIRECTIONS

The ATTENTION and BAOICHE trials showed a benefit of EVT for patients with severe symptoms from an acute BAO. However, the strong evidence about EVT for BAO was derived from Chinese Han patients, who had a higher rate of intracranial arterial stenosis than non-Asians. Hence, more RCTs are needed to study the effectiveness and safety in other ethnic groups with BAO.

Meanwhile, the radiographic assessment of posterior circulation stroke (PCS) is relatively poor in comparison with anterior circulation stroke (ACS). Non-contrast CT (NCCT) with CT perfusion (CTP) has been applied to identify ACS patients with salvageable tissue for EVT.⁷ However, the diagnostic utility of CTP and NCCT was limited in PCS due to the influence of blood flow velocity and bony structure of the posterior fossa.¹⁶ The diagnosis of PCS still depends on the diffusion-weighted MRI, which has a lower utilisation in emergency department due to availability issue and a longer scanning time.¹⁷ Therefore, exploring a rapid imaging assessment of PCS remains important.

Furthermore, BAOCHE and ATTENTION mainly enrolled patients with either a baseline NIHSS score ≥ 6 or ≥ 10 . For those outside of this range, EVT still needs more evidence. The subgroup analyses in BASICS and BAOCHE found that patients with a baseline NIHSS score of 10–20 benefited more from EVT.^{10,13} Recent evidence also found no benefit of EVT for patients with severe stroke (NIHSS score ≥ 35).¹⁸ Of note, the successful recanalisation in patients with mild BAO strokes could not guarantee good long-term clinical outcomes since these patients may have other poor predictors such as delay of treatment and other high-risk vascular factors.¹⁹ Therefore, it still remained uncertain for the effectiveness and safety of EVT in BAO patients with mild or severe symptoms. Selecting appropriate individuals for EVT should be implemented in clinical practice.

In summary, our findings demonstrated that EVT may be associated with improved clinical outcomes for selected acute BAO patients when compared with SMT.

Contributors JX and XC performed the analysis, JX, XC and SDC drafted the manuscript. YD, WC, HZ, WN, YZ, CG, YG and XC revised the manuscript. YD and QD conceived this study, supervised the analysis and finalised the manuscript.

Funding The authors have not declared a specific grant for this research from any funding agency in the public, commercial or not-for-profit sectors.

Competing interests None declared.

Patient consent for publication Not applicable.

Ethics approval Not applicable.

Provenance and peer review Not commissioned; externally peer reviewed.

Supplemental material This content has been supplied by the author(s). It has not been vetted by BMJ Publishing Group Limited (BMJ) and may not have been peer-reviewed. Any opinions or recommendations discussed are solely those of the author(s) and are not endorsed by BMJ. BMJ disclaims all liability and responsibility arising from any reliance placed on the content. Where the content includes any translated material, BMJ does not warrant the accuracy and reliability of the translations (including but not limited to local regulations, clinical guidelines, terminology, drug names and drug dosages), and is not responsible for any error and/or omissions arising from translation and adaptation or otherwise.

Open access This is an open access article distributed in accordance with the Creative Commons Attribution Non Commercial (CC BY-NC 4.0) license, which permits others to distribute, remix, adapt, build upon this work non-commercially, and license their derivative works on different terms, provided the original work is

properly cited, appropriate credit is given, any changes made indicated, and the use is non-commercial. See: <http://creativecommons.org/licenses/by-nc/4.0/>.

ORCID iDs

Jiawen Xu <http://orcid.org/0000-0002-8787-5592>
 Wenjie Cao <http://orcid.org/0000-0003-3438-3882>
 Hongchen Zhao <http://orcid.org/0000-0002-1310-1172>
 Yuxiang Gu <http://orcid.org/0000-0002-4580-2205>
 Xin Cheng <http://orcid.org/0000-0001-7816-0547>
 Yi Dong <http://orcid.org/0000-0001-6630-112X>
 Qiang Dong <http://orcid.org/0000-0002-3874-0130>

REFERENCES

- Mattle HP, Arnold M, Lindsberg PJ, *et al*. Basilar artery occlusion. *Lancet Neurol* 2011;10:1002–14.
- Schonewille WJ, Wijman CAC, Michel P, *et al*. Treatment and outcomes of acute basilar artery occlusion in the basilar artery international cooperation study (basics): a prospective registry study. *Lancet Neurol* 2009;8:724–30.
- Berkhemer OA, Fransen PSS, Beumer D, *et al*. A randomized trial of intraarterial treatment for acute ischemic stroke. *N Engl J Med* 2015;372:11–20.
- Goyal M, Demchuk AM, Menon BK, *et al*. Randomized assessment of rapid endovascular treatment of ischemic stroke. *N Engl J Med* 2015;372:1019–30.
- Jovin TG, Chamorro A, Cobo E, *et al*. Thrombectomy within 8 hours after symptom onset in ischemic stroke. *N Engl J Med* 2015;372:2296–306.
- Saver JL, Goyal M, Bonafe A, *et al*. Stent-retriever thrombectomy after intravenous t-PA vs. t-PA alone in stroke. *N Engl J Med* 2015;372:2285–95.
- Albers GW, Marks MP, Kemp S, *et al*. Thrombectomy for stroke at 6 to 16 hours with selection by perfusion imaging. *N Engl J Med* 2018;378:708–18.
- Nogueira RG, Jadhav AP, Haussen DC, *et al*. Thrombectomy 6 to 24 hours after stroke with a mismatch between deficit and infarct. *N Engl J Med* 2018;378:11–21.
- Román LS, Menon BK, Blasco J, *et al*. Imaging features and safety and efficacy of endovascular stroke treatment: a meta-analysis of individual patient-level data. *Lancet Neurol* 2018;17:895–904.
- Langezaal LCM, van der Hoeven EJRJ, Mont'Alverne FJA, *et al*. Endovascular therapy for stroke due to basilar-artery occlusion. *N Engl J Med* 2021;384:1910–20.
- Liu X, Dai Q, Ye R, *et al*. Endovascular treatment versus standard medical treatment for vertebrobasilar artery occlusion (best): an open-label, randomised controlled trial. *Lancet Neurol* 2020;19:115–22.
- Tao RL C, Zhu Y, *et al*. Endovascular treatment for acute basilar artery occlusion: a multicenter randomized clinical trial (attention). *European Stroke Organisation Conference* 2022.
- C WC L, Wu L, *et al*. Basilar artery occlusion Chinese endovascular. *European Stroke Organisation Conference* 2022.
- Nguyen TN, Strbian D. Endovascular therapy for stroke due to basilar artery occlusion: a basic challenge at best. *Stroke* 2021;52:3410–3.
- Nogueira RG LX, Vos JA, Dai Q, *et al*. Vertebrobasilar occlusion randomization to endovascular reperfusion versus intravenous thrombolysis or medical treatment alone. systematic evaluation (veritas) collaboration. *International Stroke Conference* 2021.
- Katyal A, Calic Z, Killingsworth M, *et al*. Diagnostic and prognostic utility of computed tomography perfusion imaging in posterior circulation acute ischemic stroke: a systematic review and meta-analysis. *Eur J Neurol* 2021;28:2657–68.
- Simonsen CZ, Madsen MH, Schmitz ML, *et al*. Sensitivity of diffusion- and perfusion-weighted imaging for diagnosing acute ischemic stroke is 97.5%. *Stroke* 2015;46:98–101.
- Kong W, Yuan J, Huang J, *et al*. Outcomes of endovascular therapy in acute basilar artery occlusion with severe symptoms. *JAMA Netw Open* 2021;4:e2139550.
- Guenego A, Dargazanli C, Weisenburger-Lile D, *et al*. Thrombectomy for basilar artery occlusion with mild symptoms. *World Neurosurg* 2021;149:e400–14.