
SUPPLEMENTARY MATERIALS

**Associations Between Hemodynamics and Wall Enhancement of Intracranial
Aneurysm**

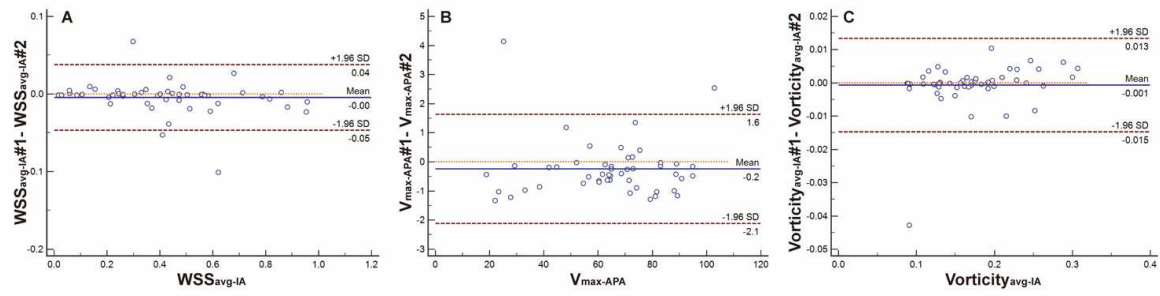
Supplementary Table 1 Scan parameters of T1-VISTA and 4D-flow MRI.

	T1-VISTA	4D-flow MRI
TR/TE (ms)	800/21	8.0/3.6
FOV	200 x 180 x 40	160 x 160 x 30
Resolution (mm)	0.6 x 0.6 x 0.6	1 x 1 x 1
flip angle	Variable ¹	20
VENC (cm/s)	—	120

VENC = Velocity encoding

Reference:

1. Qiao Y, Steinman DA, Qin Q, Etesami M, Schär M, Astor BC, Wasserman BA. Intracranial arterial wall imaging using three-dimensional high isotropic resolution black blood MRI at 3.0 Tesla. *J Magn Reson Imaging*. 2011;34:22–30.



Supplementary Figure 1 Bland-Altman plots for the interobserver reliability of continuous statistically significant variables measurement.

(A) WSS_{avg-IA} , (B) $V_{max-APA}$, and (C) $Vorticity_{avg-IA}$.