


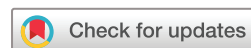# Classification of brain arteriovenous malformations located in motor-related areas based on location and anterior choroidal artery feeding

Yuming Jiao <sup>1,2,3,4</sup>, Hao Li,<sup>1,2,3,4</sup> Weilun Fu,<sup>1,2,3,4</sup> Jiancong Weng,<sup>1,2,3,4</sup> Ran Huo,<sup>1,2,3,4</sup> Yinyan Wang,<sup>1,2,5</sup> Shuo Wang,<sup>1,2,3,4</sup> Tao Jiang,<sup>1,2,5</sup> Yong Cao,<sup>1,2,3,4</sup> Ji Zong Zhao<sup>1,2,3,4</sup>

**To cite:** Jiao Y, Li H, Fu W, et al. Classification of brain arteriovenous malformations located in motor-related areas based on location and anterior choroidal artery feeding. *Stroke & Vascular Neurology* 2021;**6**: e000591. doi:10.1136/svn-2020-000591

► Additional material is published online only. To view, please visit the journal online (<http://dx.doi.org/10.1136/svn-2020-000591>).

Received 20 August 2020  
Revised 11 December 2020  
Accepted 30 December 2020  
Published Online First  
16 February 2021



© Author(s) (or their employer(s)) 2021. Re-use permitted under CC BY-NC. No commercial re-use. See rights and permissions. Published by BMJ.

For numbered affiliations see end of article.

**Correspondence to**  
Dr Yong Cao; caoyong@bjtth.org

Professor Tao Jiang;  
taojiang1964@163.com

## ABSTRACT

**Objective** Surgical management of arteriovenous malformations (AVMs) involving motor cortex or fibre tracts (M-AVMs) is challenging. This study aimed to construct a classification system based on nidus locations and anterior choroidal artery (AChA) feeding to pre-surgically evaluate motor-related and seizure-related outcomes in patients undergoing resection of M-AVMs.

**Methods and materials** A total of 125 patients who underwent microsurgical resection of M-AVMs were retrospectively reviewed. Four subtypes were identified based on nidus location: (I) nidus involving the premotor area and/or supplementary motor areas; (II) nidus involving the precentral gyrus; (III) nidus involving the corticospinal tract (CST) and superior to the posterior limb of the internal capsule; (IV) nidus involving the CST at or inferior to the level of posterior limb of the internal capsule. In addition, we divided type IV into type IVa and type IVb according to the AChA feeding. Surgical-related motor deficit (MD) evaluations were performed 1 week (short-term) and 6 months (long-term) after surgery.

**Results** The type I patients exhibited the highest incidence (62.0%) of pre-surgical epilepsy among the four subtypes. Multivariate analysis showed that motor-related area subtypes ( $p=0.004$ ) and diffuse nidus ( $p=0.014$ ) were significantly associated with long-term MDs. Long-term MDs were significantly less frequent in type I than in the other types. Type IV patients acquired the highest proportion (four patients, 25.0%) of long-term poor outcomes (mRS  $>2$ ). Type IVb patients showed a significantly higher incidence of post-surgical MDs than type IVa patients ( $p=0.041$ ). The MDs of type III or IV patients required more recovery time. Of the 62 patients who had pre-surgical seizures, 90.3% (56/62) controlled their seizures well and reached Engel class I after surgery.

**Conclusions** Combining the consideration of location and AChA feeding, the classification for M-AVMs is a useful approach for predicting post-surgical motor function and decision-making.

## INTRODUCTION

Surgical management of arteriovenous malformations (AVMs) involving motor-related cortex or fibre tracts (M-AVMs) is challenging. The case selection of surgeons

depends on a sophisticated understanding of the clinical characteristics of motor-related brain structures. To date, no specific classifications regarding M-AVMs exist to the best of our knowledge. The most frequently used prediction model, the Spetzler-Martin (S-M) grading system, included the primary motor cortex (precentral gyrus) as eloquence.<sup>1</sup> Nevertheless, the definition of eloquence of location is inadequate. First, it does not include the subcortical cortical spinal tract (CST).<sup>2</sup> Second, functional MRI studies identified the important roles of the premotor area (PMA) and supplementary area (SMA) in motor function,<sup>3-5</sup> whereas the S-M grading system does not include the PMA and SMA. In addition, our previous study indicated that anterior choroidal artery (AChA) feeding is a risk factor for post-surgical poor outcomes of AVMs, but the S-M grading system does not take feeding arteries into consideration.<sup>6</sup> According to the literature and our clinical practice, the characteristics and surgical outcomes of AVMs may differ among different motor-related areas and arterial supply.<sup>7</sup> However, the literature regarding M-AVMs is limited to small series or case reports.

Seizure is a common symptom of patients with supratentorial AVMs, especially M-AVMs.<sup>8-9</sup> Uncontrolled epilepsy may result in considerably diminished patient quality-of-life. However, the significance of seizure control is often under-appreciated in the surgical management of AVMs. Potential risks of epilepsy in patients with different subtypes of M-AVMs and freedom from seizures after surgery remain incompletely understood. A classification system for pre-surgically evaluating the surgical outcomes, especially motor function and seizure control, is needed. To date, no

such classification system regarding microsurgery for M-AVMs exists to guide neurosurgeons.

Advances in imaging techniques present new opportunities to select individual patients more safely. With diffusion tensor imaging (DTI) tractography, the spatial relationship between the CST and AVM nidus can be easily visualised.<sup>10</sup> Our study aimed to construct a classification system for patients undergoing resection of M-AVMs based on nidus locations on both cortical and subcortical levels. We reviewed all the brain M-AVMs in our hospital in the past 7 years and attempted to determine their surgical outcomes and identify the risk factors for postoperative neurological deficits in M-AVMs located in different subtypes. Detailed clinical characteristics and functional changes were compared among different subtypes. Both functional and angioarchitectural variables were analysed with respect to surgical outcomes in patients with M-AVMs. We hypothesised that this proposed classification system could improve the management of patients undergoing surgery for M-AVMs.

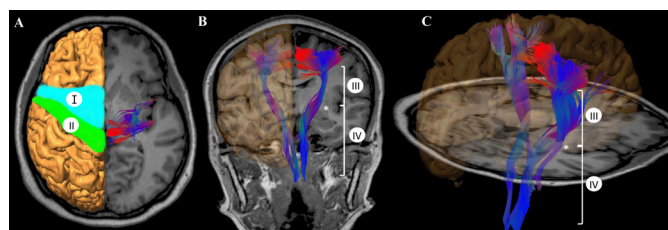
## METHODS AND MATERIALS

### Study population

A total of 125 M-AVMs that underwent microsurgical resection were retrospectively selected from our AVM database of two prospective clinical trials (ClinicalTrials.gov Identifier: NCT01758211 and NCT02868008) between September 2012 and December 2019.

### Motor-related area classifications

According to previous studies and clinical practice, four motor-related area subtypes were identified based on nidus location: (I) nidus involving PMA and/or SMAs; (II) nidus involving the precentral gyrus; (III) nidus involving the CST and superior to the posterior limb of the internal capsule; (IV) nidus that invaded the CST at or inferior to the level of posterior limb of the internal capsule.<sup>7</sup> If more than one motor-related area was invaded, the nidus was sequentially classified as the highest number of the subtypes (figure 1). In addition,



**Figure 1** Classification of motor-related eloquent areas on different planes. (A) On axial plane; (B) on coronal plane; (C) on sagittal plane. Type I, nidus involving premotor area and/or supplementary motor areas; type II, nidus involving the precentral gyrus; type III, nidus involving the corticospinal tract (CST) and superior to the posterior limb of the internal capsule; type IV, nidus that invaded the CST at or inferior to the level of posterior limb of the internal capsule. Asterisk refers to the level of internal capsule.

the deep perforating artery supply was taken into consideration. We divided type IV into type IVa (nidus without AChA feeding) and type IVb (nidus with AChA feeding). The nidus location was identified using TOF-MRA and DTI tractography images. Nidus was defined as involving the CST if the shortest distance from a nidus to the CST was less than 5 mm based on DTI tractography.

### Neuroimaging

Sagittal T1-weighted anatomical MR images, time-of-flight (TOF) MRA and DT images were obtained using a 3.0 T MR scanner (SIEMENS Trio) as previously reported.<sup>11</sup> The acquired image data were analysed on the iPlan cranial 3.0 workstation (Brainlab). Image co-registration and fusion were performed using an automatic rigid registration. Two regions of interest delineated in the precentral gyrus (seed) and pons (target) were used to track the CST.<sup>12</sup>

### Surgery

Surgical removal of AVMs was performed by an experienced physician (YC). A neuronavigation system was used to help preserve white matter tracts. Intraoperative electrophysiology monitoring and motor area mapping were used to identify the motor cortex and CST. Intraoperative indocyanine fluorescence angiography and ultrasonography were used to discern the feeding arteries and nidus margin of AVMs. Digital subtraction angiography (DSA) was performed after surgery to validate radical obliteration.

### Muscle strength evaluation

Muscle strength assessments (Medical Research Council Scores 0–5) were performed 1 day preoperatively, 1 week postoperatively (short-term) and up to 6 months postoperatively (long-term). Follow-up information from the period during the recovery of motor function was obtained by telephonic interviews. The recovery time of the motor deficits was recorded. The standard of recovery was defined as patients recovering to the level of being able to carry out all usual activities despite some symptoms (modified Rankin Scale (mRS) ≤1). Long-term good outcomes were defined as mRS 0–2, and poor outcomes were defined as mRS >2 at 6 months. The surgical complications in this study included intracranial infection, rehaemorrhage and cerebral infarction.

### Variables

The nidus size, eloquence, S-M grade, and presence of deep venous drainage and deep perforating arterial feeders were determined through preoperative angiograms.<sup>13</sup> Deep perforating arteries included the medial lenticulostriates, lateral lenticulostriate arteries, anterior and posterior choroidal arteries, thalamoperforators and brainstem perforators.<sup>14</sup> Haemorrhagic presentation was defined as radiographic evidence of haemorrhage on CT or MRI. Diffuseness was determined from preoperative angiograms and using TOF to identify intervening brain parenchyma within the nidus.

**Table 1** Demographic and angioarchitectural characteristics of patients with M-AVMs

Variables	I	II	III	IV	Total
Age (years)	27.9±12.1	26.1±14.4	22.6±12.7	29.1±16.6	26.3±13.4
Male sex (%)	31 (62.0)	15 (60.0)	16 (47.1)	7 (43.8)	69 (55.2)
Side (left)	20 (40.0)	11 (44.0)	15 (44.1)	9 (56.2)	55 (44.0)
Size	37.4±13.6	31.2±18.0	40.8±15.9	34.1±13.6	36.8±15.2
Haemorrhage*	9 (18.0)	10 (40.0)	8 (23.5)	6 (37.5)	33 (26.4)
Deep perforating artery supply	6 (12.0)	3 (12.0)	14 (41.2)	13 (81.2)	36 (28.8)
Deep venous drainage	0 (0)	1 (4.0)	3 (8.8)	8 (50.0)	12 (9.6)
Diffuseness	14 (28.0)	6 (24.0)	15 (44.1)	5 (31.2)	40 (32.0)
Mean Spetzler-Martin grade	2.1±0.8	2.6±0.6	2.9±0.6	3.1±0.6	2.6±0.8
Complications†	4 (8.0)	1 (4.0)	5 (14.7)	3 (18.8)	13 (10.4)

\*Preoperative haemorrhage presentation.

†Surgical complications, including intracranial infection, rehaemorrhage and cerebral infarction.

M-AVM, arteriovenous malformation located in motor-related areas.

### Statistical analyses

Statistical analyses were performed with SPSS V.20.0.0. Categorical variables are summarised as frequency counts and percentages and were compared using the  $\chi^2$  test or Fisher's exact test. Continuous variables are summarised as means±SD and were compared using an independent samples t-test. Postoperative short-term and long-term mRS scores were analysed to identify the surgical outcomes. The association between the variables and surgery-related motor deficits (MDs) was analysed using univariate and multivariate analyses. Variables with p value <0.1 in the univariate analysis were then used in the multivariate analysis model. For the recovery time of motor deficits, Kaplan-Meier survival analysis was applied to illustrate the time-to-recover curves. The log-rank test was used to compare differences among motor-related area subtypes. Statistical tests were considered significant at p value <0.05. ORs and HRs are presented with 95% CIs.

## RESULTS

### Clinical characteristics

A total of 125 patients with M-AVM were included in this study (table 1). There were 69 (55.2%) male patients and 56 (44.8%) female patients, with a mean age of 26.3±13.4 years. There were 12 (9.6%), 44 (35.2%), 57 (45.2%) and 12 (9.6%) patients scored S-M grade I, II, III and IV, respectively. Thirty-three (26.4%) patients had preoperative haemorrhages. The mean nidus diameter was 36.8 mm (5.0–93.6 mm). Forty patients (32.0%) had a diffuse nidus, and 85 patients (68%) had a compact nidus. The number of patients with nidus involving I, II, III and IV were 50 (40.0%), 25 (20.0%), 34 (27.2%) and 16 (12.8%), respectively.

There were no statistically significant differences in terms of the patient age (p=0.270) and sex (p=0.403) among the different subtypes. For the AVM characteristics, deep perforating arteries were more common in type

III (41.2%) and type IV (81.2%) AVM cases (p<0.001). Deep venous drainage was more common in type IV AVM cases (50%, p<0.001). There were no differences in nidus diffuseness, size (p=0.334), haemorrhage (p=0.148) and post-surgical complications (p=0.350) among these four subtype groups.

### Preoperative seizure

In our cohort, the incidence of preoperative epilepsy differed among the four subtypes. There were 31 (62.0%) in type I patients, 12 (48.0%) in type II patients, 12 (35.3%) in type III patients and 7 (43.8%) in type IV patients with an epileptic history before surgery. For the seizure types, patients in the type I group had a higher incidence (56%) of generalised tonic-clonic seizures than patients in the other groups (online supplemental table S1). Table 2 summarizes the preoperative antiepileptic drug use and the indications for surgery.

### Risk factors for MDs

Radical obliteration was achieved in all patients according to postoperative DSA. Sixty-one (48.8%) patients suffered from short-term MDs 1 week after surgery. According to the univariate analysis, significant differences in motor-related area subtypes (p<0.001), diffuseness (p=0.004), size (p=0.010), deep perforating artery supply (p=0.032) and S-M grade (p<0.001) were found between the patient cohorts with and without postoperative short-term MDs. No significant difference was found in the other factors (online supplemental table S2). According to the multivariate analysis, motor-related area subtypes (p=0.003) and diffuseness (p=0.042) were significantly associated with an increased risk of short-term MDs. No significant difference was found in the other factors (table 3).

At the follow-up after 6 months, 45 (36.0%) patients suffered from different levels of long-term MDs. Only 10 (7.8%) patients had a mRS >2 as a poor outcome. According to the univariate analysis, significant differences in motor-related area subtypes (p=0.002), diffuseness (p=0.008),

**Table 2** Preoperative antiepileptic drug use and the indications for surgery

Motor-related area subtypes	Anti-epileptic drug use	Indications for surgery				
		Severe headache	Intractable seizures	Low S-M grade	Progressive neurological deficits	Previous haemorrhages
I	31 (62.0)	3 (6.0)	25 (50.0)	13 (26.0)	0 (0.0)	9 (18.0)
II	11 (44.0)	2 (8.0)	5 (20.0)	3 (12.0)	5 (20.0)	10 (40.0)
III	12 (35.3)	5 (14.7)	11 (32.4)	1 (2.9)	10 (29.4)	8 (23.5)
IV	7 (43.8)	1 (6.2)	4 (25.0)	1 (6.2)	5 (31.2)	6 (37.5)
Total	61 (48.8)	9 (7.2)	45 (36.0)	17 (13.6)	19 (15.2)	33 (26.4)

S-M grade, Spetzler-Martin grade.

S-M grade ( $p=0.027$ ), deep perforating artery supply ( $p=0.038$ ) and deep venous (DV) drainage ( $p=0.044$ ) were found between the patient cohorts with and without postoperative MDs. No significant difference was found in the other factors (table 4). According to the multivariate analysis, motor-related area subtypes ( $p=0.004$ ) and diffuse nidus ( $p=0.014$ ) were significantly associated with an increased risk of motor deficits. We compared the predictive accuracy of the motor-related area subtypes and S-M grade by constructing receiver operating characteristic (ROC) curves. A higher area under ROC curve (0.70 vs 0.63) of the new classification than SM grade was observed (online supplemental figure S1). No significant difference was found in the other factors (table 3).

### Proportion of MDs

Different proportions of short-term ( $p<0.001$ ) and long-term ( $p=0.005$ ) MDs were observed among the four subtypes. The post-surgical short-term MDs were significantly more frequent in type III patients than in type I ( $p<0.001$ ) or type II ( $p=0.047$ ) patients. The post-surgical short-term MDs were significantly less frequent in type I patients than in type II ( $p=0.009$ ), type III or type IV ( $p=0.002$ ) patients (online supplemental table S2). For long-term MDs, post-surgical MDs were significantly less frequent in type I patients than in type II ( $p=0.009$ ), type

III ( $p<0.001$ ) or type IV ( $p=0.004$ ) patients. Although the type IV patients did not suffer from the highest proportion of postoperative MDs, they acquired the highest proportion (four patients, 25.0%) of long-term poor outcomes (mRS  $>2$ ) compared with type I (two patients, 4.0%), type II (0 patients, 0%) and type III (four patients, 11.8%) patients. The difference between type IV and type I ( $p=0.041$ ) patients and type IV and type II ( $p=0.018$ ) patients was significant (figure 2). In addition, type IVb patients showed a significantly higher incidence of post-surgical MDs than type IVa ( $p=0.041$ ) patients (table 5).

### Muscle strength recovery time

The muscle strength recovery time differed in different subtypes (figure 3). The mean recovery time was  $0.96\pm 2.0$  months in type I,  $1.72\pm 2.3$  months in type II,  $3.2\pm 2.6$  months in type III and  $3.6\pm 2.6$  months in type IV patients. A Mann-Whitney U test revealed that compared with that of type I or II patients, the muscle strength of type III or IV patients required more days to recover (type I vs III,  $p<0.001$ ; type II vs III,  $p=0.029$ ; type I vs IV,  $p<0.001$ ; type II vs IV,  $p=0.018$ ).

### Postoperative seizure control

With regular antiepileptic drugs, of the 62 patients who had a preoperative seizure history, 90.3% of these patients

**Table 3** Multivariate logistic regression analysis of predictors of postoperative motor deficits (MDs)

Variable	Short-term MD			Long-term MD		
	OR	95% CI	P value	OR	95% CI	P value
Motor-related area subtypes			<b>0.003</b>			<b>0.004</b>
I			Reference			Reference
II	3.54	1.17 to 10.72	<b>0.026</b>	4.65	1.50 to 14.39	<b>0.008</b>
III	9.11	2.85 to 29.14	<b>&lt;0.001</b>	4.80	1.72 to 13.57	<b>0.003</b>
IV	3.72	0.93 to 14.79	<b>0.063</b>	7.22	2.00 to 26.05	<b>0.014</b>
Size	1.01	0.97 to 1.06	0.491	1.00	0.97 to 1.03	0.840
Deep venous drainage	1.33	0.22 to 8.19	0.755	2.47	0.53 to 11.44	0.248
Diffuseness	2.65	1.04 to 6.79	<b>0.042</b>	2.90	1.24 to 6.78	<b>0.014</b>
Spetzler-Martin score	0.84	0.95 to 3.57	0.070	0.95	0.39 to 2.31	0.910
Perforating artery	1.74	0.51 to 6.03	0.377	1.04	0.33 to 3.33	0.942

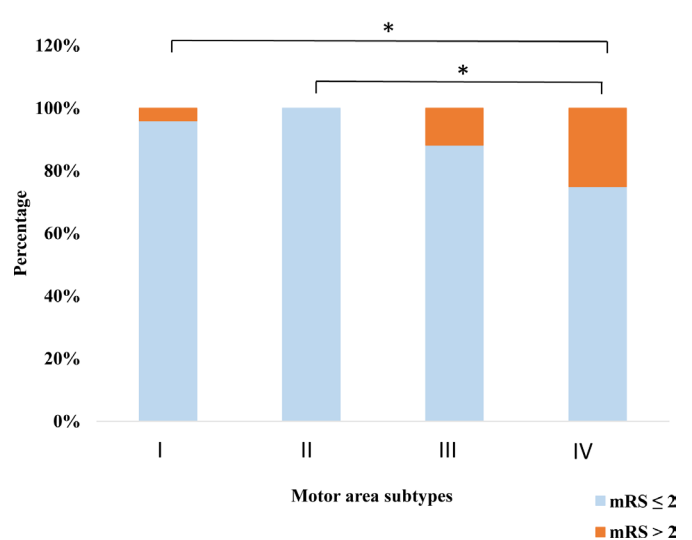
**Table 4** Univariate analysis of predictors of postoperative long-term motor deficits (MDs)

Variable	Long-term MD		P value
	No N (%)	Yes N (%)	
Patients	80 (64.0)	45 (36.0)	
Age (years)	25.4±12.8	27.9±14.4	0.308
Sex			0.664
Male	43 (62.3)	26 (37.7)	
Female	37 (66.1)	19 (33.9)	
Size	5.8±13.6	38.4±17.6	0.359
Haemorrhage			0.636
No	60 (65.2)	32 (34.8)	
Yes	20 (60.6)	13 (39.4)	
Deep venous drainage			<b>0.044</b>
No	76 (67.3)	37 (32.7)	
Yes	4 (33.3)	8 (66.7)	
Diffuse nidus			<b>0.008</b>
No	61 (54.4)	24 (28.2)	
Yes	19 (47.5)	21 (52.5)	
Motor-related area subtypes			<b>0.002</b>
I	42 (84.0)	8 (16.0)	
II	14 (56.0)	11 (44.0)	
III	17 (50.0)	17 (50.0)	
IV	7 (43.8)	9 (56.2)	
Preoperative seizure			0.905
No	40 (63.5)	23 (36.5)	
Yes	40 (64.5)	22 (35.5)	
Deep perforating artery supply			<b>0.038</b>
No	62 (69.7)	27 (30.3)	
Yes	18 (50.0)	18 (50.0)	
Spetzler-Martin score	2.5±0.8	2.8±0.8	<b>0.027</b>

(56/62) controlled their seizures well and reached Engel class I after tumour resection. Three patients (4.8%) were classified as Engel class II. Two patients (3.2%) were classified as Engel class III. Moreover, one patient (1.6%) was classified as Engel class IV. There were no significant differences among these four subtypes.

## DISCUSSION

The present study confirms our hypothesis that AVM motor eloquence subtype does have an influence on outcome following resection. We found that type I AVMs may strengthen the recommendation for surgery considering the high incidence of preoperative seizure, the relatively low rate of post-surgical MDs and the satisfactory post-surgical seizure control. When the nidus was involving CST at or below the level of posterior limb

**Poor surgical outcomes of different motor-related area subtypes**


**Figure 2** Poor surgical outcomes of arteriovenous malformations located in motor-related areas involving different motor-related area subtypes. The x-axis indicates the motor-related area subtypes. The y-axis indicates the percentage of good and poor surgical outcomes (\* $p < 0.05$ ).

of the internal capsule, especially fed by the AChA, the microsurgical treatment decision should be prudently appraised in light of the surgical risk and natural history of AVMs.

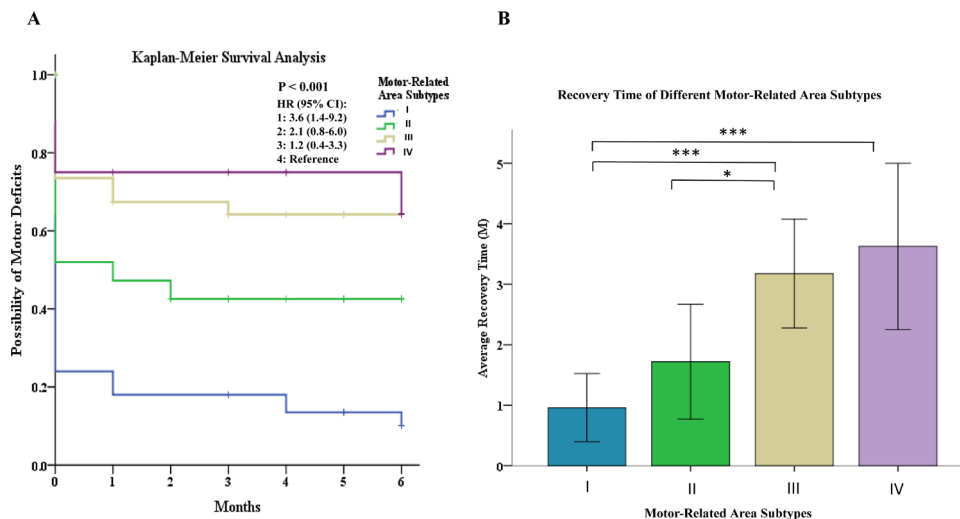
## Postoperative functional MDs

According to present data, post-surgical motor status was different among the subtypes. A high incidence of poor outcomes were observed in patients with type IV AVMs. We attribute it to two main reasons. First, according to our previous data, the CST level involved may be associated with surgical outcomes. CST rupture below the corona radiata seemed to be correlated with poor long-term outcomes. The sample size in that study was small (only 1).<sup>15</sup> Our present data validated the conclusion with a larger sample size. Second, a higher incidence of deep perforating arteries and DV drainage was observed in type IV AVMs than in the other types. According to the literature, the DV drainage and perforating artery supply are

**Table 5** Comparison of surgical outcomes of patients with type IV M-AVMs

Variables	Subtypes of type IV		P value
	IVa N (%)	IVb N (%)	
Short-term MD	3 (37.5)	7 (87.5)	0.119
Long-term MD	2 (25.0)	7 (87.5)	<b>0.041</b>
Poor outcome	2 (25.0)	2 (25.0)	1.00
Recovery time (months)	2.5±1.7	4.7±1.9	0.08
Complications	0 (0)	3 (37.5)	0.20

M-AVM, arteriovenous malformation located in motor-related areas; MD, motor deficit.



**Figure 3** Recovery time of motor deficits in arteriovenous malformations (AVMs) located in motor-related areas involving different motor-related area subtypes. (A) Kaplan-Meier survival plots for AVMs according to months of motor deficit recovery. The x-axis indicates completed months of follow-up. (B) Bar graph showing the average recovery time of different motor-related area subtypes (\* $p < 0.01$ ; \*\*\* $p < 0.001$ ).

friable, resist bipolar coagulation and have the dangerous propensity to retract. Their deep location can limit visualisation and overall operative manoeuvrability, and adds a unique set of dangers to AVM resection.<sup>16</sup> In our study, there were 14 (41.2%) type III and 13 (81.2%) type IV patients with nidus existing in deep perforating arteries, while there were 3 (8.8%) and 8 (50.0%) patients with existing DV drainage. Accordingly, in our opinion, the poor outcomes in type III patients were more associated with damage to the adjacent eloquent areas, while type IV patients were associated with both damage to adjacent eloquent areas and angioarchitectural characteristics.

In this study, 22% (11/50) of type I patients suffered from short-term motor strength deficits. This could be due to postoperative supplementary motor area syndrome.<sup>17</sup> The PMA and SMA contribute significantly to the control of hand movements required for the manipulation of objects.<sup>18</sup> In 16% (8/60) of type I patients, there was no recovery of MDs to normal 6 months after surgery. The proportion was lowest among the four subtypes but still higher than that of glioma resection in this area. In previous studies, infarction or resection of the PMA or SMA in gliomas often leads to weakness of muscles or akinesia, which can resolve spontaneously and completely within days to months.<sup>19–21</sup> We speculated that the delayed recovery was associated with resection of the cingulate cortex and its deep regions or interruption of the CST.<sup>16</sup> Different from cerebral infarctions or gliomas, in surgery for AVMs, rough nidus margins and intermixed adjacent brain tissue force the surgeon to damage the functional fibres when resecting the nidus.

### Subtypes of type IV

In our previous study, we described that surgical treatment of AVMs supplied by the AChA, especially the cisternal segment, can cause a high incidence of MDs.<sup>6</sup>

Therefore, we divided type IV into type IVa (nidus without AChA feeding) and type IVb (nidus with AChA feeding). Consistent with our speculation, a significant difference in long-term MDs was observed between the two groups. In addition to the anatomy location, these data indicated that the feeding arteries have a great effect on the surgical outcomes of M-AVMs. The AChA nourishes many important anatomical structures such as the internal capsule, the lateral geniculate body and the thalamus.<sup>12,13</sup> During the surgical treatment of M-AVMs, the feeding arteries must be ligated to facilitate the resection.<sup>22</sup> Brain AVMs supplied by cisternal segment of AChA was an independent risk factor for postoperative MDs because the perforating branches of the cisternal segment of the AChA do not receive any significant collateral supply.<sup>6</sup> In this study, patients with a nidus located in a type IVb area was mostly fed by the cisternal part of the AChA, so the effect of AChA feeding is mainly affecting MDs of type IV patients.

### Recovery time

According to present data, the recovery time after surgery differed among different subtypes. Patients with type I AVMs needed the shortest recovery thanks to the mild motor deficits. In contrast, patients with type III or type IV AVMs needed the longest recovery time resulting from the relatively severe MDs. It was worth mentioning that patients with AVMs involving motor fibres (types III and IV) needed longer recovery times than those with AVMs involving the motor cortex (type II), although they were both primary eloquent motor areas. We attributed it to two reasons. The first one is the different recovery power between the motor cortex and subcortical CST. According to the literature, distinct to the cortex, subcortical pathways are difficult to compensate for, especially pathways responsible for a single function. Therefore,

the rupture of the CST may need a longer time to reorganise.<sup>23</sup> Second, we speculate that this difference is also a result of the larger potential of cortical reorganisation in patients with type II AVMs. There is a consensus that AVMs develop in early life.<sup>24</sup> According to previous studies, the brain cortex has great ability to reorganise in the setting of a chronic disease, with displacement to homologous regions on the contralateral side or adjacent regions on the ipsilateral side.<sup>25 26</sup> The reorganisation may facilitate motor recovery after the surgery-related injury of the brain cortex.

### Epileptic status

A high incidence (62%) of preoperative seizures was observed in type I AVMs, which is higher than that of seizures due to frontal AVMs reported in the literature (39%). In a previous study, Hamasaki *et al* demonstrated the higher incidence of epilepsy in meningiomas located on the PMA.<sup>27</sup> In addition, Wang *et al* demonstrated that increased seizure risks were identified for low-grade gliomas that involved the PMA using voxel-based lesion-symptom mapping.<sup>28</sup> Literature about the epileptic status of patients with AVMs located in the PMA or SMA were limited to case reports. Our study showed the high incidence of epilepsy in these areas. After surgery, satisfactory seizure control was achieved. In our series, 88% of patients with type I AVMs who underwent surgery were seizure free or Engel class I at the 6-month follow-up.

### Other factors related to post-surgical MD

According to present data, nidus diffuseness was independently associated with short-term and long-term MDs. This outcome was in concordance with previous studies.<sup>14 29 30</sup> Compact M-AVMs have distinct borders so that clear dissection can be achieved between brain tissue and nidus, whereas a diffuse nidus can force the surgeon to dissect too close to the nidus, resulting in unexpected bleeding, or resect interspersed brain, which might injure the eloquent motor cortex or CST.<sup>16</sup>

### Study limitations

Our study had several limitations. First, this study was conducted in a single centre. Second, due to its retrospective nature, it may be difficult to avoid information bias, selection bias and confounding factors. Third, although the sample size in this study may be one of the largest regarding the study of M-AVMs, to the best of our knowledge, the sample size was still not large enough because there were only 16 patients in the type IV group. Meanwhile, the limited number of outcomes may result in over-fitting of the model when the statistical model contains more parameters than can be justified by the data. Thus, further validation with more patients and a prospective approach should be performed.

### CONCLUSIONS

The motor-related area classification system for M-AVMs provides an observational tool in patients with M-AVMs.

Based on our results and the literature, we propose some suggestions for patient selection in surgically treating this challenging entity. Considering the high incidence of preoperative seizure (especially the generalised tonic-clonic subtype), the satisfying post-surgical seizure control and the relatively low rate of post-surgical MD, the recommendation for surgery of type I AVMs may be strengthened. Great caution should be taken in the resection of type II and III AVMs to avoid postoperative MDs, especially type III. A longer recovery time was needed for type III AVMs than for type II AVMs. Moreover, the AChA feeding should also be taken into consideration when classifying M-AVMs. For the type IV AVMs, especially type IVb, because of the high proportion of poor post-surgical outcomes, the microsurgical treatment decision should be prudently appraised in light of the surgical risk and natural history of AVMs.<sup>31</sup> In our opinion, conservative treatment may be recommended for type IVb patients without a history of bleeding or intractable seizure. If the surgery were chosen for the aforementioned reasons, radiosurgery, embolisation, or a combination of microsurgery and embolisation can be recommended, whereas the benefits of these treatment modalities require validation in further research.

### Author affiliations

<sup>1</sup>Department of Neurosurgery, Beijing Tiantan Hospital, Capital Medical University, Beijing, China

<sup>2</sup>China National Clinical Research Center for Neurological Diseases, Beijing, China

<sup>3</sup>Center of Stroke, Beijing Institute for Brain Disorders, Beijing, China

<sup>4</sup>Beijing Key Laboratory of Translational Medicine for Cerebrovascular Disease, Beijing, China

<sup>5</sup>Beijing Neurosurgical Institute, Capital Medical University, Beijing, China

**Contributors** Conception and design: YC, YJ, TJ. Acquisition of data: YJ, JW, YW, WF. Analysis and interpretation of data: YJ, YW, HL, YC. Drafting the article: YJ. Critically revising the article: YC, YJ, TJ. Reviewed submitted version of manuscript: all authors. Approved the final version of the manuscript on behalf of all authors: YC, TJ. Statistical analysis: YJ, YW, HL. Administrative/technical/material support: YC, TJ, SW, JZZ. Study supervision: YC, TJ, JZZ.

**Funding** This study was supported by the National Natural Science Foundation of China (Grant No. 81901175, Principal Investigator: YJ), the "National key research and development program of China during the 13th Five-Year Plan Period" (Grant No. 2016YFC1301803, Principal Investigator: YC; and Grant No. 2016YFC1301801, Principal Investigator: SW).

**Competing interests** None declared.

**Patient consent for publication** Not required.

**Ethics approval** This study complied with the Declaration of Helsinki, adhered to the Good Clinical Practice guideline and was approved by the Ethics Committee of the Beijing Tiantan Hospital Affiliated with Capital Medical University (KY2016-031-01). Written informed consent was obtained from all participants or their legally authorised representative.

**Provenance and peer review** Not commissioned; externally peer reviewed.

**Data availability statement** Data are available on reasonable request. Deidentified participant data are available on reasonable request.

**Open access** This is an open access article distributed in accordance with the Creative Commons Attribution Non Commercial (CC BY-NC 4.0) license, which permits others to distribute, remix, adapt, build upon this work non-commercially, and license their derivative works on different terms, provided the original work is properly cited, appropriate credit is given, any changes made indicated, and the use is non-commercial. See: <http://creativecommons.org/licenses/by-nc/4.0/>.

## ORCID iD

Yuming Jiao <http://orcid.org/0000-0001-8351-4602>

## REFERENCES

- 1 Spetzler RF, Martin NA. A proposed grading system for arteriovenous malformations. *J Neurosurg* 1986;65:476–83.
- 2 Jiao Y, Lin F, Wu J, et al. A supplementary grading scale combining lesion-to-eloquence distance for predicting surgical outcomes of patients with brain arteriovenous malformations. *J Neurosurg* 2018;128:530–40.
- 3 Jiao Y, Lin F, Wu J, et al. Brain arteriovenous malformations located in premotor cortex: surgical outcomes and risk factors for postoperative neurologic deficits. *World Neurosurg* 2017;105:432–40.
- 4 Picard N, Strick PL. Activation of the supplementary motor area (SMA) during performance of visually guided movements. *Cereb Cortex* 2003;13:977–86.
- 5 Chouinard PA, Paus T. The primary motor and premotor areas of the human cerebral cortex. *Neuroscientist* 2006;12:143–52.
- 6 Jiao Y, Lin F, Wu J, et al. Brain arteriovenous malformations supplied by the anterior choroidal artery: treatment outcomes and risk factors for worsened muscle strength after surgical resection. *World Neurosurg* 2017;104:567–74.
- 7 Fang S, Li Y, Wang Y, et al. Awake craniotomy for gliomas involving motor-related areas: classification and function recovery. *J Neurooncol* 2020;148:317–25.
- 8 Englot DJ, Young WL, Han SJ, et al. Seizure predictors and control after microsurgical resection of supratentorial arteriovenous malformations in 440 patients. *Neurosurgery* 2012;71:572–80.
- 9 Shankar JJS, Menezes RJ, Pohlmann-Eden B, et al. Angioarchitecture of brain AVM determines the presentation with seizures: proposed scoring system. *AJNR Am J Neuroradiol* 2013;34:1028–34.
- 10 Catani M, Thiebaut de Schotten M. A diffusion tensor imaging tractography atlas for virtual in vivo dissections. *Cortex* 2008;44:1105–32.
- 11 Lin F, Jiao Y, Wu J, et al. Effect of functional MRI-guided navigation on surgical outcomes: a prospective controlled trial in patients with arteriovenous malformations. *J Neurosurg* 2017;126:1863–72.
- 12 Okada T, Miki Y, Kikuta K, et al. Diffusion tensor fiber tractography for arteriovenous malformations: quantitative analyses to evaluate the corticospinal tract and optic radiation. *American Journal of Neuroradiology* 2007;28:1107–13.
- 13 Spetzler RF, Martin NA. A proposed grading system for arteriovenous malformations. *J Neurosurg* 2008;108:186–93.
- 14 Lawton MT, Kim H, McCulloch CE, et al. A supplementary grading scale for selecting patients with brain arteriovenous malformations for surgery. *Neurosurgery* 2010;66:702–13.
- 15 Lin F, Wu J, Zhao B, et al. Preoperative functional findings and surgical outcomes in patients with motor cortical arteriovenous malformation. *World Neurosurg* 2016;85:273–81.
- 16 Du R, Keyoung HM, Dowd CF, et al. The effects of diffuseness and deep perforating artery supply on outcomes after microsurgical resection of brain arteriovenous malformations. *Neurosurgery* 2007;60:638–48.
- 17 Abel TJ, Buckley RT, Morton RP, et al. Recurrent supplementary motor area syndrome following repeat brain tumor resection involving supplementary motor cortex. *Neurosurgery* 2015;11 Suppl 3:447–55.
- 18 Potgieser ARE, de Jong BM, Wagemakers M, et al. Insights from the supplementary motor area syndrome in balancing movement initiation and inhibition. *Front Hum Neurosci* 2014;8:960.
- 19 Ibe Y, Tosaka M, Horiguchi K, et al. Resection extent of the supplementary motor area and post-operative neurological deficits in glioma surgery. *Br J Neurosurg* 2016;30:323–9.
- 20 Vassal M, Charroud C, Deverduin J, et al. Recovery of functional connectivity of the sensorimotor network after surgery for diffuse low-grade gliomas involving the supplementary motor area. *J Neurosurg* 2017;126:1181–90.
- 21 Nakajima R, Kinoshita M, Yahata T, et al. Recovery time from supplementary motor area syndrome: relationship to postoperative day 7 paralysis and damage of the cingulum. *J Neurosurg* 2019:1–10.
- 22 Hashimoto N, Nozaki K, Takagi Y, et al. Surgery of cerebral arteriovenous malformations. *Neurosurgery* 2007;61:SHC-375–SHC-389.
- 23 Herbet G, Maheu M, Costi E, et al. Mapping neuroplastic potential in brain-damaged patients. *Brain* 2016;139:829–44.
- 24 Gross BA, Du R. Natural history of cerebral arteriovenous malformations: a meta-analysis. *J Neurosurg* 2013;118:437–43.
- 25 Alkadhi H, Kollias SS, Crelier GR, et al. Plasticity of the human motor cortex in patients with arteriovenous malformations: a functional MR imaging study. *AJNR Am J Neuroradiol* 2000;21:1423–33.
- 26 Deng X, Zhang Y, Xu L, et al. Comparison of language cortex reorganization patterns between cerebral arteriovenous malformations and gliomas: a functional MRI study. *J Neurosurg* 2015;122:996–1003.
- 27 Hamasaki T, Yamada K, Yano S, et al. Higher incidence of epilepsy in meningiomas located on the premotor cortex: a voxel-wise statistical analysis. *Acta Neurochir* 2012;154:2241–9.
- 28 Wang Y, Qian T, You G, et al. Localizing seizure-susceptible brain regions associated with low-grade gliomas using voxel-based lesion-symptom mapping. *Neuro Oncol* 2015;17:282–8.
- 29 Spears J, TerBrugge KG, Moosavian M, et al. A discriminative prediction model of neurological outcome for patients undergoing surgery of brain arteriovenous malformations. *Stroke* 2006;37:1457–64.
- 30 Hartmann A, Stapf C, Hofmeister C, et al. Determinants of neurological outcome after surgery for brain arteriovenous malformation. *Stroke* 2000;31:2361–4.
- 31 Laakso A, Dashti R, Juvela S, et al. Risk of hemorrhage in patients with untreated Spetzler-Martin grade IV and V arteriovenous malformations: a long-term follow-up study in 63 patients. *Neurosurgery* 2011;68:372–7.