

Recanalisation therapy in patients with acute ischaemic stroke caused by large artery occlusion: choice of therapeutic strategy according to underlying aetiological mechanism?

Chenglin Tian, Xiangyu Cao, Jun Wang

To cite: Tian C, Cao X, Wang J. Recanalisation therapy in patients with acute ischaemic stroke caused by large artery occlusion: choice of therapeutic strategy according to underlying aetiological mechanism?. *Stroke and Vascular Neurology* 2017;2:e000090. doi:10.1136/svn-2017-000090

Received 4 April 2017
Revised 8 June 2017
Accepted 7 July 2017
Published Online First
1 August 2017

ABSTRACT

Various mechanisms underlie causative large artery occlusion (LAO) in patients with acute ischaemic stroke. Cardioembolic and atherosclerotic occlusions are the two most common types. The pathophysiological changes and responses to mechanical thrombectomy (MT) and antithrombotic treatments including thrombolysis, antiplatelet and anticoagulation therapy may vary among patients with different aetiological mechanisms of occlusion. Atherosclerotic occlusion is inclined to have relatively abundant collaterals and larger area of penumbra, hence a relatively wider time window for reperfusion therapy, while poor response to medical thrombolysis and MT. Severe residual stenosis and reocclusion occurred frequently after MT in atherosclerotic LAO. Angioplasty and stenting as rescue or the first-line therapy and more intensified antiplatelet therapy beyond related recommendations in the current guidelines are sometimes used in managing acute causative LAO because of poor recanalisation after recommended standard thrombolysis or MT therapy, which are usually based on individual experience. Standard protocol to establish emergent aetiological diagnosis of causative LAO and individualised aetiology-specific treatment strategy is needed.

INTRODUCTION

In 2015, the benefit of mechanical thrombectomy (MT) for acute ischaemic stroke (AIS) was documented in five clinical trials.^{1–5} MT mainly through stent retrieval has been recommended as the standard treatment for causative proximal large artery occlusion (LAO) of anterior circulation.⁶ The key criteria for MT include causative occlusion of the internal carotid artery (ICA) or proximal middle cerebral artery (MCA), National Institute of Health Stroke Scale (NIHSS) score of ≥ 6 , Alberta Stroke Program Early CT Score of ≥ 6 , and treatment can be initiated (groin puncture) within 6 hours of symptom onset. Use of MT was also considered reasonable for carefully selected patients who have causative

occlusion of the M2 or M3 portion of the MCAs, anterior cerebral arteries, vertebral arteries, basilar artery or posterior cerebral arteries.⁶ Various mechanisms underlie causative LAO in patients with AIS. Cardioembolism (CE), in situ thrombosis (IST) on the surface of a vulnerable atherosclerotic plaque with severe or slight stenosis, chronic atherosclerotic occlusion, artery-to-artery embolism caused by a detached in situ thrombus or intrinsic component of a proximal atherosclerotic plaque and other rare causes such as vasculitis and dissection all can result in the similar clinical vignette of AIS associated with a LAO on angiographic imaging (figure 1). The pathophysiological changes and responses to MT and antithrombotic treatments including thrombolysis, antiplatelet and anticoagulation therapy may vary among patients with different aetiological mechanisms of occlusion. However, aetiological mechanisms of LAO were not included in the recommended criteria for selecting recanalisation strategy. In this review, we summarised the pathophysiological features of causative LAO resulting from different aetiological mechanisms. Their possible impact on choice MT, antithrombotic therapeutic strategy and statin therapy was discussed.

IMPACT OF AETIOLOGICAL MECHANISMS UNDERLYING LAO ON COLLATERAL STATUS IN AIS

Cerebral collateral circulation provides subsidiary blood flow to oligemia brain tissue when the primary feeding artery is severely stenosed or occluded. The artery anatomy of collateral circulation includes the Circle of Willis (CW), large-artery communications between the extracranial artery and intracranial artery and leptomeningeal anastomoses that links distal sections of major cerebral arteries.



CrossMark

Department of Neurology, The Chinese PLA General Hospital, Beijing, China

Correspondence to

Dr Chenglin Tian;
tianchenglin719@aliyun.com

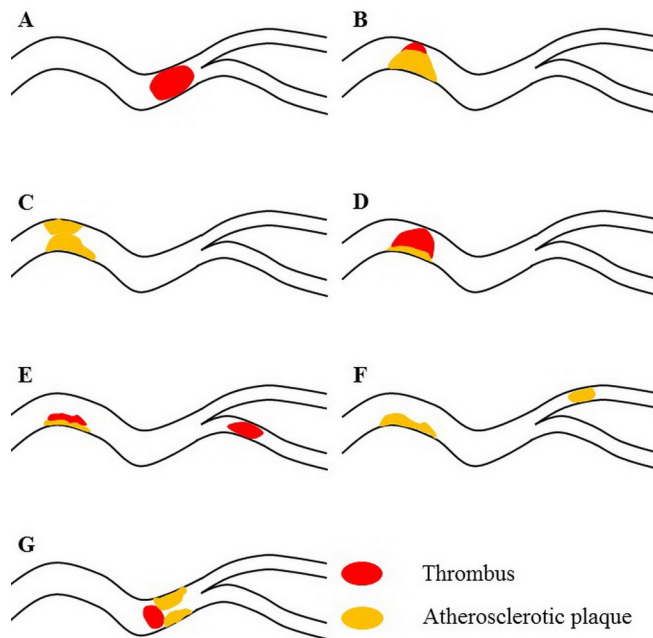


Figure 1 Illustrative of aetiological mechanisms of large artery occlusion. (A) cardioembolism; (B) in situ thrombosis on atherosclerotic plaque with severe stenosis; (C) chronic atherosclerotic occlusion; (D) in situ thrombosis on atherosclerotic plaque with slight stenosis; (E) artery-to-artery embolism from in situ thrombus; (F) artery-to-artery embolism from atherosclerotic plaque; and (G) cardioembolism in combination with atherosclerotic stenosis.

The former is considered as primary collateral and the latter two as secondary collaterals.⁷ The effectiveness of primary collaterals mainly relies on the integrity of the CW. A complete CW, if exists, is usually robust enough to compensate the decreased blood flow caused by a chronic or even abrupt occlusion lying proximally to it. However, absence or hypoplasia of one or more segments of CW is not rare,⁸ which may impair its effectiveness of redistributing blood. Capacity of secondary collaterals such as leptomeningeal anastomoses is affected by much more factors than primary collaterals is. Great variation exists in secondary collateral status of healthy adults. Animal studies demonstrated that genetic background might determine collaterals development at embryo stage and the final extent of collaterals in adulthood.^{9 10} Acquired factors including age, history of hypertension, smoking and atherosclerosis might also influence leptomeningeal anastomoses.^{7 11} Another important factor affecting secondary collateral status is the speed of occlusion. When the anatomy of secondary collaterals is present, relatively more time is still needed to recruit them because of their narrow calibre (50–400 μm). When leptomeningeal artery anastomoses is scarce, collaterals might occur through neovascularisation that is a long-lasting pathophysiological process. So, in patients with LAO distal to CW, collateral status may be greatly influenced by their underlying aetiological mechanisms. Atherosclerotic severe stenosis or occlusion, which typically presents a

chronic process, is more favourable for development of collaterals in comparison with abrupt occlusion caused by embolus originating from heart or proximal artery. It is understandable that AIS caused by atherosclerotic stenosis or occlusion is inclined to have abundant collaterals and relatively larger area of penumbra, hence a relatively wider time window for reperfusion therapy. In the Warfarin Aspirin Symptomatic Intracranial Disease trial, severe intracranial arterial stenosis was proved to be an important determinant of pial collateral circulation.¹² Kim *et al* found that intracranial large artery atherosclerotic stroke had different perfusion-weighted imaging–diffusion-weighted imaging mismatch profiles from those of CE stroke, which was related to better collaterals.¹³ CE stroke was also proved to have higher baseline NIHSS score, larger baseline infarct volume and larger infarct volume growth.¹⁴ When LAO is caused by acute IST on a vulnerable plaque without severe stenosis, change of collateral status is most likely similar to that after embolic occlusion.

IMPACT OF AETIOLOGICAL MECHANISMS UNDERLYING LAO ON THE OUTCOMES OF RECANALISATION THERAPY

Recanalisation therapy involving intravenous thrombolysis and MT have been recommended as the first-line therapeutic protocol for AIS due to LAO. Moreover, successful recanalisation correlates closely, though not necessarily, with favourable clinical outcomes.^{15 16} Aetiological mechanisms underlying occlusion classified according to the Trial of Org 10172 in Acute Stroke Treatment (TOAST) criteria has been demonstrated to influence the effect of recanalisation therapy in some series of AIS treated with thrombolysis. In a series of 72 patients with AIS caused by proximal MCA occlusion and treated with intravenous alteplase in 3 hours, recanalisation was earlier, faster and more complete in CE stroke compared with large artery atherosclerotic stroke.¹⁷ A retrospective analysis of data collected from 1031 consecutive patients with AIS treated with intravenous thrombolysis found that disappearance of hyperdense MCA sign, a surrogate imaging marker of successful recanalisation, was more common in CE stroke than in large artery atherosclerotic stroke.¹⁸ No recanalisation was observed in 49% of atherosclerotic group, while in only 2% of CE group in a series of 76 patients treated with intra-arterial (IA) pro-urokinase.¹⁹ Some imaging features of the occluded segments of artery might reflect the aetiological mechanisms of occlusion and be used as an imaging marker to predict the effect of recanalisation therapy. In a systematic review, hyperdense thrombi were found to be associated with higher proportion of red blood cell components, which may be a histological marker of CE, although controversy still exists.²⁰ Thrombi with lower density on non-contrast CT (NCCT) appeared to be more resistant to both pharmacological lysis and MT.^{21–23} Permeability of thrombus was associated with the rate of successful recanalisation after intravenous alteplase treatment.^{24 25} Previous thrombi

most likely are those newly formed cardiogenic or in situ thrombi.

IMPACT OF AETIOLOGICAL MECHANISMS UNDERLYING LAO ON RESIDUAL STENOSIS AND REOCCLUSION AFTER MT

In LAO caused by proximally originating embolus, which can be either arterial or cardiogenic, the embolus resides in the site of occlusion where the artery is not wide enough to allow its pass and contacts the vessel wall loosely without tissue junction. It should be more easily to be cleared by stent retrieval or aspiration. The vessel wall is more likely to remain undamaged after successful recanalisation. In LAO caused by IST secondary to atherosclerotic lesion, culprit plaques underlying IST are usually attached to the vessel wall tightly and are relatively difficult to be removed by endovascular procedure. It is reasonable to speculate that residual stenosis is more common in atherosclerotic LAO after MT. In fact, fixed focal stenosis after primary MT procedure, either stent retrieval or aspiration, has been usually considered as the angiographic marker suggesting occlusion due to atherosclerotic lesions.^{26–30} When the thrombus resulting from IST is removed by endovascular procedure or medically lysed, the underlying culprit plaque with or without additional procedure related damage is exposed to blood again. The process of IST might repeat at the top of original plaque and result in reocclusion.³¹ Histopathological analysis of retrieved thrombus showed that atheromatous gruel component was associated with less frequent successful reperfusion.³² In several case series of intracranial LAO receiving endovascular revascularisation, instant reocclusion during procedure occurred frequently^{26–29} and was significantly more common in atherosclerotic LAO than in LAO secondary to CE.^{27 29 30} Final degree of revascularisation was relatively poor in atherosclerotic LAO even rescue angioplasty and/or stent were employed.^{28 30} In a series of acute vertebrobasilar occlusion, clinical outcome was poorer in atherosclerotic group than in CE group despite the similar rate of final successful recanalisation.²⁹

ROLE OF ANGIOPLASTY AND STENTING IN AIS DUE TO LAO

In the five randomised clinical trials that validated MT for AIS, endovascular intervention procedure did not involve angioplasty or stenting even if successful recanalisation was not achieved by MT.^{1–5} Carotid angioplasty was only allowed for the purpose of intracranial access in ‘Solitaire with the Intention for Thrombectomy as Primary Endovascular Treatment (SWIFT PRIME) trial’.³ However, severe residual stenosis after primary MT constitutes a common clinical dilemma during endovascular treatment of AIS especially in Asian patients with disproportionately more intracranial atherosclerosis than whites.^{33 34} When severe residual stenosis exists after primary MT, additional angioplasty with or without stenting seems to be an appealing therapeutic procedure to achieve satisfying recanalisation. However, the value of intracranial angioplasty and stenting has not been well established in

either chronic or acute symptomatic intracranial stenosis. In patients with recent transient ischaemic attack or stroke related to 70%–99% stenosis of a major intracranial artery, aggressive medical management plus percutaneous transluminal angioplasty and stenting turned out to be of no benefit in comparison with aggressive medical management alone.^{35 36} The expected benefits of revascularisation by angioplasty and stenting derive from reducing future ischaemic events in chronic symptomatic intracranial stenosis, while angioplasty and stenting might produce additional benefits by restoring blood perfusion to penumbra area in AIS when satisfying recanalisation is not achieved by MT. So, the results of clinical trials evaluating angioplasty and stenting in intracranial stenosis may not be applicable to AIS due to intracranial atherosclerosis. Angioplasty with or without stenting as the first-line procedure, or as rescue procedure in thrombolysis resistant or MT refractory intracranial occlusion, has been reported to be safe and feasible and yields high rate of revascularisation in several case series of AIS.^{26 28 29 37–39} However, solid evidence supporting emergent angioplasty with or without stenting in AIS is still lacking. The more complex and time-consuming procedure and bleeding risk related to more intensive antiplatelet therapy after the procedure might counterbalance the potential benefits resulting from revascularisation. Further research is needed to validate the value of emergent angioplasty and stenting in AIS.

IMPACT OF AETIOLOGICAL MECHANISMS UNDERLYING LAO ON CHOICE OF ANTIPLATELET STRATEGY AFTER RECANALISATION THERAPY IN AIS

Benefits of intravenous alteplase within 4.5 hours and oral administration of aspirin within 24–48 hours after stroke onset as early secondary prevention have been well established, and they were recommended in early management of AIS.⁴⁰ However, intravenous thrombolysis rules out administration of aspirin or other antiplatelet agents within the following 24 hours according to the current guidelines.⁴⁰ ‘The 2015 American Heart Association/American Stroke Association focused update of 2013 Guidelines for the early management of patients with AIS regarding endovascular treatment’ did not provide any revision about administration of antiplatelet agents,⁶ which mean that antiplatelet is not recommend immediately after medical thrombolysis, MT or bridging therapy. However, as we have discussed in the second part, reocclusion is a major issue of concern after endovascular recanalisation therapy, especially in atherosclerotic occlusion. Reocclusion diminish the benefit of thrombolysis in AIS patients with MCA occlusion as well.^{41 42} After alteplase thrombolysis, reocclusion was more common in patients with partial recanalisation⁴² and those with ipsilateral carotid disease,⁴¹ which indicates that reocclusion inclines to occur in patients with atherosclerotic disease after medical thrombolysis. Fibrinolytic substance and atherosclerotic lesions might jointly induce activation of

platelets and secondary thrombus formation that results in reocclusion.^{43 44} Based on such mechanisms of reocclusion, antiplatelet agents is speculated to be the most promising drugs to prevent reocclusion. However, early administration of intravenous aspirin started within 90 min after initiation of intravenous alteplase has turned out to be of no benefit. Patients receiving aspirin were more than twice as likely to develop symptomatic intracranial haemorrhage as the group given intravenous alteplase alone.⁴⁵ Glycoprotein IIb/IIIa receptor inhibitors are potent agents affecting platelet aggregation. Three intravenously deliverable glycoprotein IIb/IIIa receptor inhibitors including abciximab, eptifibatide and tirofiban have been tested for the treatment of acute cerebrovascular diseases. Tirofiban differs pharmacologically from abciximab and eptifibatide. It has a biological half-life of 4–8 hours. Platelet function returned in 2 hours when stopped,⁴⁶ which might make tirofiban a more desirable glycoprotein IIb/IIIa receptor inhibitors in AIS. Acceptable safety outcomes and more favourable function outcomes have been reported in small case series of AIS treated with tirofiban alone,⁴⁷ tirofiban in combination with intravenous or IA thrombolysis^{47–49} and tirofiban in combination with bridging therapy,^{50 51} respectively. In a prospective, randomised, placebo-controlled, open-label treatment phase II trial, tirofiban did not increase the risk of cerebral haemorrhagic transformation (HT) and parenchymal haemorrhage but may decrease the mortality rate at 5 months.⁵² In managing severe residual stenosis or reocclusion after MT that usually occurred in atherosclerotic occlusion, rescue angioplasty with or without stenting is increasingly used in clinical practice,^{27–30 37 39} although not routinely recommended by the current guidelines. Angioplasty or stenting necessitate the early administration of intensified antiplatelet therapy as it is routinely used before and after opening chronic stenosis by angioplasty with or without stenting.^{35 53} Intravenous administration of tirofiban is now the most commonly used antiplatelet therapy following rescue angioplasty with or without stenting.^{27 29 30} Tirofiban has been reported to facilitate further recanalisation by repeated MT when primary MT failed.⁵⁴ Despite the prevailing empirical administration of tirofiban in AIS, the indication, optimal dose and duration of tirofiban in causative LAO have not been well established. Additionally, the currently available evidence is not yet solid enough to overcome the concern about the potentially increased risk of HT. Restricting more intensified antiplatelet therapy to more precisely selected patients with lower risk of HT is reasonable. Patients with AIS due to atherosclerotic LAO are more likely to gain benefit from administration of tirofiban after recanalisation therapy than those with LAO resulting from CE since CE turns out to be an independent risk factor for HT after recanalisation therapy.^{55–57} In 80 patients with causative occlusion of MCA or ICA, atrial fibrillation (AF), the predominant risk factor of CE, was significantly associated with intracerebral haemorrhage after combined intravenous and IA thrombolysis.⁵⁷ In a retrospective analysis of

1122 consecutive patients presenting to 13 high-volume stroke centres with AIS due to proximal occlusion in the anterior circulation who underwent endovascular treatment within 8 hours from symptom onset, patients with AF had a higher risk of parenchymal haemorrhage.⁵⁶ CE stroke also increased the risk of symptomatic intracerebral haemorrhage in stroke patients treated with stent-like retrievers for reopening a LAO in anterior circulation from 21 stroke centres in China.⁵⁸ Additionally, HT constitutes a major contributor to worse outcome in AF patients receiving recanalisation therapy.^{56 59}

IMPACT OF AETIOLOGICAL MECHANISMS UNDERLYING LAO ON THE EFFECT OF STATIN IN AIS

Statins have cholesterol-lowering and pleiotropic effects including altering the expression of endothelial nitric oxide synthase, proinflammatory cytokines and reactive oxygen species and the reactivity of platelets, which might produce beneficial effect on cerebral haemodynamics and stabilisation of atherosclerotic plaques.^{60 61} Statins may, however, influence bleeding risk, which is the main adverse event observed in AIS with recanalisation therapies. The contributions of statin to clinical outcomes remain a matter of debate. In a large-scale meta-analysis including 27 studies, prestroke statin use was associated with improved outcome in AIS; however, the finding was not repeated in studies restricted to thrombolysis-treated patients.⁶² Prestroke statin use shows neither independent beneficial effect on functional outcomes nor independent detrimental effect on the risk of intracerebral haemorrhage in two other systematic reviews that evaluated the effect of statin use on outcomes after intravenous thrombolysis and/or IA thrombolysis.^{63 64} In a more recent systematic review, however, statin was found to be associated with good functional outcome while an increased risk of symptomatic HT in patients treated with thrombolysis.⁶⁵ Considering that atherosclerotic plaque is one of the major targets of statin's pleiotropic effects, atherosclerotic LAO stroke patients may gain more benefits from early and more intensified statin treatment than CE stroke patients do. Statin pretreatment was demonstrated to improve outcomes regarding neurological improvement, disability, survival and stroke recurrence in 516 consecutive first-ever AIS patients with LAO.⁶⁶ Aetiological mechanisms of LAO should be taken into account in further studies evaluating the effect of statin in patients with AIS after recanalisation therapy.

CHALLENGES IN DETERMINING THE AETIOLOGICAL MECHANISMS UNDERLYING LAO IN AIS

The prerequisite to establish individualised revascularisation strategy according to aetiological mechanism is the accurate and timely aetiological diagnosis of causative LAO. The traditional tools of aetiological diagnosis mainly include the classification systems such as TOAST system and the recently proposed Chinese Ischemic Stroke Subclassification system.^{67 68} In these systems,

clinical and imaging features of stroke in combination with existence or absence of large artery stenosis and risk factors of CE were employed to determine the underlying aetiological mechanisms in AIS. Nonetheless, these systems may not be applicable in AIS with LAO in emergency circumstance. History of AF and electrocardiography evidence of AF are often lacking in a patient with CE presenting to emergency room.⁶⁹ The atherosclerotic origin of an intracranial chronic LAO or LAO related to acute IST cannot be identified when prestroke cerebral angiographic images are not available, which constitute a tough challenge in aetiological diagnosis of intracranial atherosclerotic LAO commonly found in Asian populations. Because of the limitations of traditional classification system, new tools are needed to aid the emergency aetiological diagnosis. Although the location of occlusion, imaging features of thrombus on NCCT, contrast-enhanced CT and MRI have been proven to be associated with the causes of thrombus,^{70–76} the relatively low specificity of imaging features, time-consuming procedure of scanning and limited availability of imaging modalities all diminish their value for aetiological diagnosis in clinical practice. Recanalisation status after MT remains the most commonly used evidence to differentiate atherosclerotic occlusion from embolic occlusion.^{27–30 37 39} Nonetheless, the individual operation skills of interventional neurologists, which largely affect the final recanalisation outcomes, may confound the aetiological diagnosis. More standardised and feasible clinical routes for emergency aetiological classification of LAO await to be established.

SUMMARY

LAO can be caused by various aetiological mechanisms, among which CE and IST secondary to atherosclerotic plaque are the two most common kinds, although their proportion varied in different races. Aetiological mechanism of LAO has significant clinical implications in AIS that include:

1. impacts on collateral and perfusion status after onset of stroke
2. impacts on recanalisation and function outcomes after revascularisation therapy
3. influencing the time window of reperfusion therapy
4. influencing the choice of revascularisation procedure other than thrombolysis and MT, which includes angioplasty with or without stenting as rescue therapy or occasionally as the first-line therapy in AIS due to LAO
5. determining individualised intensity of antiplatelet therapy
6. influencing the effect of statin in AIS.

Aetiological diagnosis of LAO may constitute a key issue in management of AIS. Further clinical studies are needed to evaluate interventional procedures and antiplatelet therapies beyond those recommended in the current guidelines and guide choice of individualised aetiology-specific recanalisation and antiplatelet therapy.

Feasible and reliable tools for timely aetiological diagnosis of LAO should be developed.

Contributors All authors contributed equally.

Funding This article was funded by the Hainan Provincial Committee of Health and Family Planning. Grant No. 1423320.54A1006.

Competing interests None declared.

Provenance and peer review Not commissioned; externally peer reviewed.

Open Access This is an Open Access article distributed in accordance with the Creative Commons Attribution Non Commercial (CC BY-NC 4.0) license, which permits others to distribute, remix, adapt, build upon this work non-commercially, and license their derivative works on different terms, provided the original work is properly cited and the use is non-commercial. See: <http://creativecommons.org/licenses/by-nc/4.0/>

© Article author(s) (or their employer(s) unless otherwise stated in the text of the article) 2017. All rights reserved. No commercial use is permitted unless otherwise expressly granted.

REFERENCES

1. Berkhemer OA, Fransen PS, Beumer D, *et al.* A randomized trial of intraarterial treatment for acute ischemic stroke. *N Engl J Med* 2015;372:11–20.
2. Goyal M, Demchuk AM, Menon BK, *et al.* Randomized assessment of rapid endovascular treatment of ischemic stroke. *N Engl J Med* 2015;372:1019–30.
3. Saver JL, Goyal M, Bonafe A, *et al.* Stent-retriever thrombectomy after intravenous t-PA vs. t-PA alone in stroke. *N Engl J Med* 2015;372:2285–95.
4. Campbell BC, Mitchell PJ, Kleinig TJ, *et al.* Endovascular therapy for ischemic stroke with perfusion-imaging selection. *N Engl J Med* 2015;372:1009–18.
5. Jovin TG, Chamorro A, Cobo E, *et al.* Thrombectomy within 8 hours after symptom onset in ischemic stroke. *N Engl J Med* 2015;372:2296–306.
6. Powers WJ, Derdeyn CP, Biller J, *et al.* 2015 American Heart Association/American Stroke Association Focused Update of the 2013 guidelines for the Early Management of Patients with Acute Ischemic Stroke regarding Endovascular treatment: a guideline for Healthcare Professionals from the American Heart Association/American Stroke Association. *Stroke* 2015;46:3020–35;46:3020–35.
7. Shuaib A, Butcher K, Mohammad AA, *et al.* Collateral blood vessels in acute ischaemic stroke: a potential therapeutic target. *Lancet Neurol* 2011;10:909–21.
8. Osborn AG, Kluwer W, *Diagnostic cerebral angiography*. Second edition, 1998.
9. Zhang H, Prabhakar P, Sealock R, *et al.* Wide genetic variation in the native pial collateral circulation is a Major determinant of variation in severity of stroke. *J Cereb Blood Flow Metab* 2010;30:923–34.
10. Chalothorn D, Faber JE. Formation and maturation of the native cerebral collateral circulation. *J Mol Cell Cardiol* 2010;49:251–9.
11. Alves HC, Pacheco FT, Rocha AJ. Collateral blood vessels in acute ischemic stroke: a physiological window to predict future outcomes. *Arq Neuropsiquiatr* 2016;74:662–70.
12. Liebeskind DS, Cotsonis GA, Saver JL, *et al.* Collateral circulation in symptomatic intracranial atherosclerosis. *J Cereb Blood Flow Metab* 2011;31:1293–301.
13. Kim SJ, Seok JM, Bang OY, *et al.* MR mismatch profiles in patients with intracranial atherosclerotic stroke: a comprehensive approach comparing stroke subtypes. *J Cereb Blood Flow Metab* 2009;29:1138–45.
14. Kim HJ, Yun SC, Cho KH, *et al.* Differential patterns of evolution in acute middle cerebral artery infarction with perfusion-diffusion mismatch: atherosclerotic vs. cardioembolic occlusion. *J Neurol Sci* 2008;273:93–8.
15. Nogueira RC, Bor-Seng-Shu E, Saeed NP, *et al.* Meta-analysis of Vascular Imaging features to predict Outcome following Intravenous rTPA for Acute Ischemic stroke. *Front Neurol* 2016;7:77.
16. Lin MP, Tsvigoulis G, Alexandrov AV, *et al.* Factors affecting clinical outcome in large-vessel occlusive ischemic strokes. *Int J Stroke* 2015;10:479–84.
17. Molina CA, Montaner J, Arenillas JF, *et al.* Differential pattern of tissue plasminogen activator-induced proximal middle cerebral artery recanalization among stroke subtypes. *Stroke* 2004;35:486–90.

18. Forlivesi S, Bovi P, Tomelleri G, et al. Stroke etiologic subtype may influence the rate of hyperdense middle cerebral artery sign disappearance after intravenous thrombolysis. *J Thromb Thrombolysis* 2017;43:86-90.
19. Ueda T, Sakaki S, Kumon Y, et al. Multivariable analysis of predictive factors related to outcome at 6 months after intra-arterial thrombolysis for acute ischemic stroke. *Stroke* 1999;30:2360-5.
20. Mishra SM, Dykeman J, Sajobi TT, et al. Early reperfusion rates with IV tPA are determined by CTA clot characteristics. *AJNR Am J Neuroradiol* 2014;35:2265-72.
21. Moftakhar P, English JD, Cooke DL, et al. Density of Thrombus on admission CT predicts revascularization efficacy in large vessel occlusion acute ischemic stroke. *Stroke* 2013;44:243-5.
22. Puig J, Pedraza S, Demchuk A, et al. Quantification of Thrombus hounsfield units on noncontrast CT predicts stroke subtype and early recanalization after intravenous recombinant tissue plasminogen activator. *AJNR Am J Neuroradiol* 2012;33:90-6.
23. Froehler MT, Tateshima S, Duckwiler G, et al. The hyperdense vessel sign on CT predicts successful recanalization with the Merci device in acute ischemic stroke. *J Neurointerv Surg* 2013;5:289-93.
24. Santos EM, Dankbaar JW, Treurniet KM, et al. Permeable Thrombi are Associated with higher intravenous recombinant Tissue-Type plasminogen activator treatment success in patients with acute ischemic stroke. *Stroke* 2016;47:2058-65.
25. Santos EM, Marquering HA, den Blanken MD, et al. Thrombus permeability is Associated with Improved functional outcome and recanalization in patients with ischemic stroke. *Stroke* 2016;47:STROKEAHA.115.01187-41.
26. Lee JS, Hong JM, Lee KS, et al. Primary stent retrieval for acute intracranial large artery occlusion due to atherosclerotic disease. *J Stroke* 2016;18:96-101.
27. Kang DH, Kim YW, Hwang YH, et al. Instant reocclusion following mechanical thrombectomy of in situ thromboocclusion and the role of low-dose intra-arterial tirofiban. *Cerebrovasc Dis* 2014;37:350-5.
28. Al Kasab S, Almadidy Z, Spiotta AM, et al. Endovascular treatment for AIS with underlying ICAD. *J Neurointerv Surg* 2016;neurintsurg-2016-012529.
29. Kim YW, Hong JM, Park DG, et al. Effect of intracranial atherosclerotic disease on endovascular treatment for patients with acute vertebrobasilar occlusion. *AJNR Am J Neuroradiol* 2016;2072-8.
30. Hwang YH, Kim YW, Kang DH, et al. Impact of target arterial residual Stenosis on Outcome after Endovascular Revascularization. *Stroke* 2016;47:1850-7.
31. Cao X, Wang J, Tian C, et al. Letter by Cao et al regarding Article, "Impact of Target Arterial Residual Stenosis on Outcome After Endovascular Revascularization". *Stroke* 2016;47:e240.
32. Hashimoto T, Hayakawa M, Funatsu N, et al. Histopathologic analysis of retrieved Thrombi Associated with successful reperfusion after acute Stroke Thrombectomy. *Stroke* 2016;47:3035-7.
33. Leung SY, Ng TH, Yuen ST, et al. Pattern of cerebral atherosclerosis in Hong Kong Chinese: severity in intracranial and extracranial vessels. *Stroke* 1993;24:779-86.
34. Feldmann E, Daneault N, Kwan E, et al. Chinese-white differences in the distribution of occlusive cerebrovascular disease. *Neurology* 1990;40:1540-5.
35. Derdeyn CP, Chimowitz MI, Lynn MJ, et al. Aggressive medical treatment with or without stenting in high-risk patients with intracranial artery Stenosis (SAMMPRIS): the final results of a randomised trial. *Lancet* 2014;383:333-41.
36. Zaidat OO, Fitzsimmons BF, Woodward BK, et al. Effect of a balloon-expandable intracranial stent vs medical therapy on risk of stroke in patients with symptomatic intracranial Stenosis: the VISSIT randomized clinical trial. *JAMA* 2015;313:1240-8.
37. Brekenfeld C, Schroth G, Mattle HP, et al. Stent placement in acute cerebral artery occlusion: use of a self-expandable intracranial stent for acute stroke treatment. *Stroke* 2009;40:847-52.
38. Ringer AJ, Qureshi AI, Fessler RD, et al. Angioplasty of intracranial occlusion resistant to thrombolysis in acute ischemic stroke. *Neurosurgery* 2001;48:1282-8. discussion 1288-90.
39. Yoon W, Kim SK, Park MS, et al. Endovascular treatment and the outcomes of atherosclerotic intracranial Stenosis in patients with hyperacute stroke. *Neurosurgery* 2015;76:680-6. discussion 686.
40. Jauch EC, Saver JL, Adams HP, et al. Guidelines for the early management of patients with acute ischemic stroke: a guideline for healthcare professionals from the American Heart Association/ American Stroke Association. *Stroke* 2013;44:870-947.
41. Rubiera M, Alvarez-Sabin J, Ribo M, et al. Predictors of early arterial reocclusion after tissue plasminogen activator-induced recanalization in acute ischemic stroke. *Stroke* 2005;36:1452-6.
42. Alexandrov AV, Grotta JC. Arterial reocclusion in stroke patients treated with intravenous tissue plasminogen activator. *Neurology* 2002;59:862-7.
43. Kawano K, Aoki I, Aoki N, et al. Human platelet activation by thrombolytic agents: effects of tissue-type plasminogen activator and urokinase on platelet surface P-selectin expression. *Am Heart J* 1998;135:268-71.
44. Nordt TK, Moser M, Kohler B, et al. Augmented platelet aggregation as predictor of reocclusion after thrombolysis in acute myocardial infarction. *Thromb Haemost* 1998;80:881-6.
45. Zinkstok SM, Roos YB, ARTIS investigators. Early administration of aspirin in patients treated with alteplase for acute ischaemic stroke: a randomised controlled trial. *Lancet* 2012;380:731-7.
46. Seitz RJ, Siebler M. Platelet GPIIb/IIIa receptor antagonists in human ischemic brain disease. *Curr Vasc Pharmacol* 2008;6:29-36.
47. Zhu YQ, Zhang YJ, Ruan HL, et al. Safety of tirofiban for patients with acute ischemic stroke in routine clinical practice. *Exp Ther Med* 2015;10:169-74.
48. Li W, Lin L, Zhang M, et al. Safety and preliminary efficacy of early Tirofiban treatment after Alteplase in acute ischemic stroke patients. *Stroke* 2016;47:2649-51.
49. Seitz RJ, Meisel S, Moll M, et al. The effect of combined thrombolysis with rTPA and tirofiban on ischemic brain lesions. *Neurology* 2004;62:2110-2.
50. Mangiafico S, Cellerini M, Nencini P, et al. Intravenous glycoprotein IIb/IIIa inhibitor (tirofiban) followed by intra-arterial urokinase and mechanical thrombolysis in stroke. *AJNR Am J Neuroradiol* 2005;26:2595-601.
51. Mangiafico S, Cellerini M, Nencini P, et al. Intravenous tirofiban with intra-arterial urokinase and mechanical thrombolysis in stroke: preliminary experience in 11 cases. *Stroke* 2005;36:2154-8.
52. Siebler M, Hennerici MG, Schneider D, et al. Safety of Tirofiban in acute ischemic stroke: the SaTIS trial. *Stroke* 2011;42:2388-92.
53. Brott TG, Halperin JL, Abbara S, et al. 2011 ASA/ACCF/AHA/AANN/ AANS/ACR/ASNR/CNS/SAIP/SCAI/SIR/SNIS/SVM/SVS guideline on the management of patients with extracranial carotid and vertebral artery disease: executive summary: a report of the American College of Cardiology Foundation/American Heart Association Task Force on Practice Guidelines, and the American Stroke Association, American Association of Neuroscience Nurses, American Association of Neurological Surgeons, American College of Radiology, American Society of Neuroradiology, Congress of Neurological Surgeons, Society of Atherosclerosis Imaging and Prevention, Society for Cardiovascular Angiography and Interventions, Society of Interventional Radiology, Society of NeuroInterventional Surgery, Society for Vascular Medicine, and Society for Vascular Surgery. Developed in collaboration with the American Academy of Neurology and Society of Cardiovascular Computed Tomography. *Catheter Cardiovasc Interv* 2013;81:E76-123.
54. Seo JH, Jeong HW, Kim ST, et al. Adjuvant Tirofiban injection through Deployed Solitaire Stent as a rescue Technique after failed Mechanical Thrombectomy in Acute stroke. *Neurointervention* 2015;10:22-7.
55. Whiteley WN, Slot KB, Fernandes P, et al. Risk factors for intracranial hemorrhage in acute ischemic stroke patients treated with recombinant tissue plasminogen activator: a systematic review and meta-analysis of 55 studies. *Stroke* 2012;43:2904-9.
56. Nogueira RG, Gupta R, Jovin TG, et al. Predictors and clinical relevance of hemorrhagic transformation after endovascular therapy for anterior circulation large vessel occlusion strokes: a multicenter retrospective analysis of 1122 patients. *J Neurointerv Surg* 2015;7:16-21.
57. IMS Study Investigators. Hemorrhage in the Interventional Management of Stroke study. *Stroke* 2006;37:847-51.
58. Hao Y, Yang D, Wang H, et al. Predictors for symptomatic intracranial hemorrhage after endovascular treatment of acute ischemic stroke. *Stroke* 2017;48:1203-9.
59. Tu HT, Campbell BC, Christensen S, et al. Worse stroke outcome in atrial fibrillation is explained by more severe hypoperfusion, infarct growth, and hemorrhagic transformation. *Int J Stroke* 2015;10:534-40.
60. Oesterle A, Laufs U, Liao JK. Pleiotropic effects of statins on the Cardiovascular System. *Circ Res* 2017;120:229-43.
61. Giannopoulos S, Katsanos AH, Tsvigoulis G, et al. Statins and cerebral hemodynamics. *J Cereb Blood Flow Metab* 2012;32:1973-6.
62. Ni Chroinin D, Asplund K, Åsberg S, et al. Statin therapy and outcome after ischemic stroke: systematic review and meta-analysis of observational studies and randomized trials. *Stroke* 2013;44:448-56.

63. Meseguer E, Mazighi M, Lapergue B, *et al.* Outcomes after thrombolysis in AIS according to prior statin use: a registry and review. *Neurology* 2012;79:1817–23.
64. Engelter ST, Soinne L, Ringleb P, *et al.* IV thrombolysis and statins. *Neurology* 2011;77:888–95.
65. Hong KS, Lee JS. Statins in acute ischemic stroke: a systematic review. *J Stroke* 2015;17:282–301.
66. Tsiygoulis G, Katsanos AH, Sharma VK, *et al.* Statin pretreatment is associated with better outcomes in large artery atherosclerotic stroke. *Neurology* 2016;86:1103–11.
67. Gao S, Wang YJ, Xu AD, *et al.* Chinese ischemic stroke subclassification. *Front Neurol* 2011;2:6.
68. Adams HP, Bendixen BH, Kappelle LJ, *et al.* Classification of subtype of acute ischemic stroke. definitions for use in a multicenter clinical trial. TOAST. trial of Org 10172 in acute Stroke treatment. *Stroke* 1993;24:35–41.
69. Sposato LA, Cipriano LE, Saposnik G, *et al.* Diagnosis of atrial fibrillation after stroke and transient ischaemic attack: a systematic review and meta-analysis. *Lancet Neurol* 2015;14:377–87.
70. Hui FK, Zhu X, Jones SE, *et al.* Early experience in high-resolution MRI for large vessel occlusions. *J Neurointerv Surg* 2015;7:509–16.
71. Xu WH, Li ML, Niu JW, *et al.* Luminal thrombosis in middle cerebral artery occlusions: a high-resolution MRI study. *Ann Transl Med* 2014;2:75.
72. Liebeskind DS, Sanossian N, Yong WH, *et al.* CT and MRI early vessel signs reflect clot composition in acute stroke. *Stroke* 2011;42:1237–43.
73. Park MG, Oh SJ, Baik SK, *et al.* Susceptibility-Weighted Imaging for detection of Thrombus in acute cardioembolic stroke. *J Stroke* 2016;18:73–9.
74. Cho KH, Kim JS, Kwon SU, *et al.* Significance of susceptibility vessel sign on T2*-weighted gradient Echo imaging for identification of stroke subtypes. *Stroke* 2005;36:2379–83.
75. Yamamoto N, Satomi J, Tada Y, *et al.* Two-layered susceptibility vessel sign on 3-tesla T2*-weighted imaging is a predictive biomarker of stroke subtype. *Stroke* 2015;46:269–71.
76. Baek JH, Kim BM, Kim DJ, *et al.* Importance of truncal-type occlusion in stentriever-based thrombectomy for acute stroke. *Neurology* 2016;87:1542–50.